

Congenital Hernia of Morgagni - A Case Report

Sagar Sonawane^{1*}, M. K. Tolani², Ravindra Sonawane³, Nilesh Ahire⁴, Suhas Patil⁵ and Sandip Patil⁶

¹Associate Professor, Department of Paediatrics, Dr. Vasant Rao Pawar Medical College, Hospital and Research Centre, Adgaon, Nashik, India; drsagarsonawane22@gmail.com

²Professor, Department of Paediatrics, Dr. Vasant Rao Pawar Medical College, Hospital and Research Centre, Adgaon, Nashik, India; Tolanimk@gmail.com

³Professor, Department of Paediatrics, Dr. Vasant Rao Pawar Medical College, Hospital and Research Centre, Adgaon, Nashik, India; ravindra_sonawane2000@yahoo.com

⁴Associate Professor, Department of Paediatrics, Dr. Vasant Rao Pawar Medical College, Adgaon, Nashik, India; niviahire@yahoo.co.in

⁵Associate Professor, Department of Paediatrics, Dr. Vasant Rao Pawar Medical College, Adgaon, Nashik, India

⁶Assistant Professor, Department of Paediatrics, Dr. Vasant Rao Pawar Medical College, Adgaon, Nashik, India

Abstract

Congenital Diaphragmatic Hernia of Morgagni occurs through the foramen of Morgagni, is rare in children. It is usually asymptomatic and detected accidentally. If symptomatic, then symptoms are variable and nonspecific making diagnosis difficult. Our patient presented with signs and symptoms suggestive of congenital heart disease, gastroesophageal reflux disease and recurrent pneumonia.

Keywords: Foramen of Morgagni, Hernia of Morgagni

1. Introduction

Congenital Diaphragmatic Hernia (CDH) occurs in 1 in 3000 newborns¹. Majority occurs through the left posterolateral foramen of bochdalek and commonly these patients are symptomatic at birth². Hernia through the foramen of Morgagni which occurs in the anterior midline through the sternocostal hiatus of the diaphragm is rare in children, occurring in only 1% - 6% of all types of CDH. It is usually asymptomatic and detected accidentally, or in symptomatic patients produces variable nonspecific symptoms which include respiratory,

vague gastrointestinal or cardiac symptoms and therefore diagnosis is usually delayed^{3,4}. Our patient presented with recurrent respiratory infection, vomiting, sings, symptoms mimicking congenital heart disease and failure to thrive.

2. Case Presentation

Our patients 9 months male weight 5 kg, length 62 cm brought with complaints of cough, fever and difficulty in breathing, had similar complaints fifteen days prior, for which he was treated and improved. Child had history of

*Author for Correspondence

recurrent vomiting, regurgitation, cough while feeding since the age of three months, our patient also has failure to thrive. Patient had been evaluated for these recurrent complaints, even a color Doppler – 2 d echo was done two months back suspecting congenital heart disease showed only patent foramen oval.

On examination he had tachycardia, tachypnoea, respiratory distress, pulse was low volume on adequate hydration, anterior chest wall was bulged, on auscultation crepts in right mid zone, heart sounds muffled, X-ray chest showed right mid zone pneumonia. Patients treated with antibiotics and oxygen, fever subsided but tachypnoea persisted. Because of muffled heart sounds and tachycardia with the suspicion of congenital heart disease 2- D echo color Doppler repeated was normal except patent foramen oval ,second probable disease suspected was Gastro esophageal Reflux Disease (GERD) because of recurrent respiratory symptoms. Repeat X-ray chest done showed double shadow overlying cardiac silhouette which was not there on admission. Lateral chest X ray was done for confirmation which showed anterior morgagni's hernia which confirmed with Computed Tomography (CT SCAN) showing herniation of large intestine through the another diaphragmatic defect. Patient was successfully operated at our hospital. Postoperative patient was stable & discharged on proper dietary advice.

3. Discussion

Embryonically three elements are differentiated in muscularization of diaphragm – the pars lumbaris, costalis, and sternalis. The costalis is formed by the fibers spreading out from the tendinous center to the last six costal arches. The pars sternalis is formed from the xiphoid process, a few of them spreading to the posterior aspect of the rectus abdomens sheath.

The failure of the fusion between the fibrotendinous elements of the pars sternalis and those arising from the seven costochondral arches leaves a muscle free area, which extends from sternum medially to the eight costal cartilages laterally known as foramen of morgagni. In the morgagni hernia named, after the Morgagani who first described it in 1761, the peritoneum and the abdominal contains pass upward through this space into the thoracic cavity⁵.

The defect in the diaphragm is generally located on the right side (90%) or bilaterally (7%), occasionally it may be on the left side, as the presence of heart and pericardium

are barrier against herniation⁶. Morgagnis hernia is rare in the pediatric age group, representing between 1 to 6% of all types of CDH. Only few studies showed occurrence of up to 10%⁷. It is more common in males.

Most patients are asymptomatic, until adult hood or if symptomatic, present with repeated attacks of chest infection, gastro intestinal symptoms (vomiting, abdominal pain & bleeding) or symptoms due to compression of thoracic organs. Compression of heart mimics congenital heart disease like hypo plastic right heart syndrome⁸. The rarity of this morgagnis hernia can be associated with other anomalies like bowel malrotation, pulmonary hypoplasia, Down's syndrome, congenital heart disease⁹.

The rarity of this CDH and the non specific symptoms may lead to a delay in diagnosis, particularly in childhood. Our patient was apparently in good health for first 3 month of life then he had symptoms suggestive of recurrent chest infection, regurgitation. Three weeks prior to admission he was treated for lower respiratory tract infection , transiently improved but cough, fever & respiratory distress recurred, X ray chest showed pneumonia on right side (Figure 1).

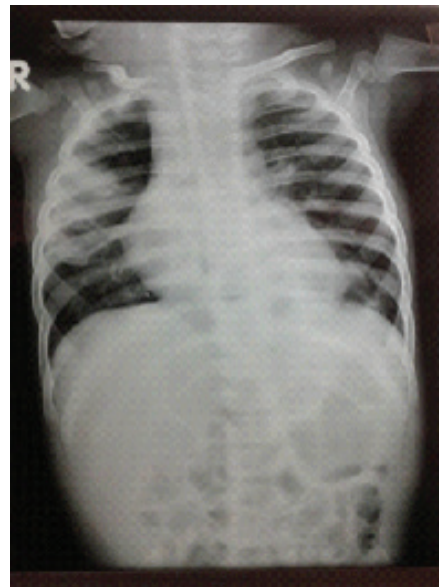

Figure 1. NTS: X- ray chest antero posterior view.

Repeat chest X ray done as tachypnoea persisted showed double shadow over the cardiac silhouette (Figure 2), lateral chest x ray done confirmed the diagnosis of morgagnis hernia compressing heart (Figure 3).

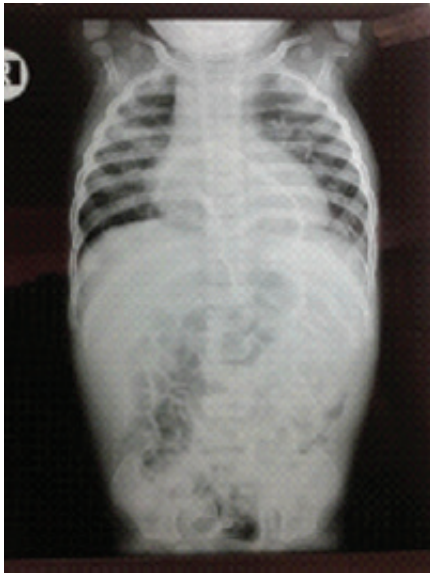

Figure 2. NTS: X- ray chest antero posterior view.

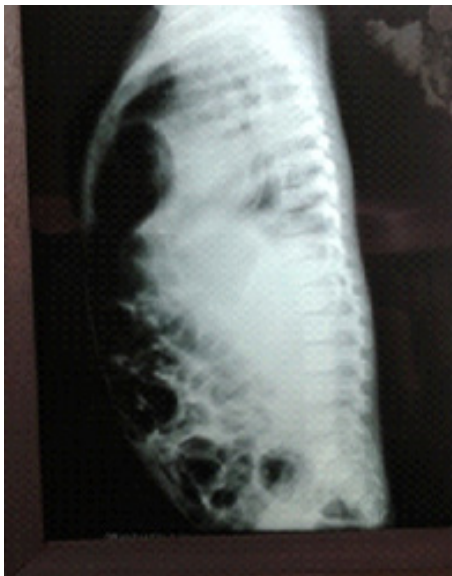

Figure 3. X-ray chest Lateral view.

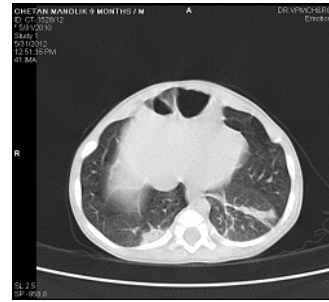


Figure 4a. CT image of infant

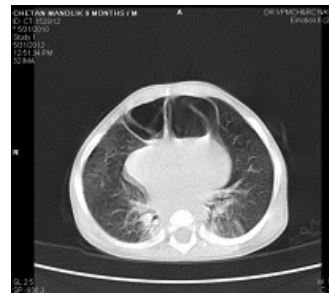


Figure 4b. CT image of infant

CT scan reveals large intestines in the thoracic cavity. Diagnosis is difficult when only omentum or liver is (Figure 4a and 4b) herniated. In these cases differential diagnosis includes pluropericardial cyst, lipoma, other intrathoracic tumors, partial eventration of diaphragm and those lung lesions which produce radiological shadow in the middle lobe area.

4. Conclusion

Morgagni's CDH is rare malformation, which is difficult to diagnose, even by the experienced physicians, strong index of suspicion is needed. Diagnosis is usually established by routine chest X ray with a lateral film to show the arterially placed bowel loops.

4.1 Competing Interest

None Stated

4.2 Authors Contribution

S S carried out the acquisition of data conception & design. M K T, R S and N A have major contribution to writing the manuscript. S.P1 & S.P2 critically revised the manuscript & M T had final approval of the version to be

published. All authors have read and approved the final manuscript.

4.3 Consent

Written informed consent was obtained from the patient's parents for the publication of this case report.

5. References

1. Schwartz DS, Johnson JI, Steinberg SR, Talevera F, Zamboni P, Milliken JC. Congenital Diaphragmatic Hernia. Available from <http://emedicine.medscape.com/article/426142>
2. Simson JNL, Eckstein HB. Congenital Diaphragmatic Hernia, a 20 year experience. *Br J Surg.* 1985; 72:733-6.
3. Cullen ML, Klein MD, Philippart Al. Congenital Diaphragmatic Hernia. *Surg Clin North Am.*1985; 65:1135-8.
4. Berman L, Stinger D, Ein SH, Shadling B. The late presenting pediatric Morgagni's hernia a benign condition. *J Pediatr Surg.* 1989; 24:970-2.
5. Paris F, Tarazona V, Casillas M, Blasco E, Canto A, Pastorg J, Acosta A. *Thorax.* 1973; 28:631-6.
6. Al-Arfugi L. A: Morgani's hernia in infants and children. *Eur J Surg.* 1998; 164:275-279.
7. Al-Salem AH. Congenital hernia of morgagni in children. *Ann Saudi Med.* 1998; 18(3): 260-2.
8. Bassareo PP, Neroni P, Montis S, Tumbarello F. Morgagni's diaphragmatic hernia mimicking a severe congenital heart disease in a newborn: a case report. *J Med Case Rep* 2010; 4:395. Available from <http://www.jmedicalcasereports.com/contact/4/1/395>
9. AL-Salem AH. Congenital Morgagni's hernia and associated anomalies. *JPSS.* 2010; 4:1-66.