

Functional Outcome of Closed Intramedullary Interlocking Nailing in Gustillo-Anderson Type I and II Compound Fractures of Femoral Shaft

¹Amit Bhasale and Satyen Joshi^{2*}

¹PG Resident, Department of Orthopaedics, Dr. Vasant Rao Pawar Medical College, Hospital and Research Centre, Nashik 422003, India

²Associate Professor, Department. of Orthopaedics, Dr. Vasant Rao Pawar Medical College, Hospital and Research Centre, Nashik 422003, India; drsatyenjoshi@gmail.com

Abstract

Background: Fractures of the shaft of the femur are among the most common fractures resulting mostly from high energy trauma. **Objectives:** To study the functional outcome of closed intramedullary interlocking nailing in Gustillo-Anderson type I and II compound fractures of femoral shaft. **Methodology:** In this prospective study, 20 adult patients with Gustillo Anderson Class I and II fractures were included. After undergoing closed intramedullary interlocking nailing, the functional outcome was assessed using the Harris Hip score. **Results and Conclusion:** Excellent or good functional outcome as per Harris Hip score was observed in 80% cases while fair results were observed in 15% cases. One case with deep wound infection and non union showed poor outcome. Interlocked intramedullary nailing system showed excellent result in both close and open fractures.

Keywords: Femur, Gustillo-Anderson type I and II, Intramedullary, Trauma

1. Introduction

Fractures of the shaft of the femur are among the most common fractures encountered in orthopaedic practice. Because the femur is the largest bone of the body and one of the principal load-bearing bones in the lower extremity, fractures can cause prolonged morbidity and extensive disability unless treatment is appropriate¹.

These fractures most often results from high energy trauma, so one must have a high index of suspicion for complications and associated injuries. In developing countries, femoral shaft fractures are commonly due to increasing incidence of Road Traffic Accident (RTA)².

Shortening of the limb and malalignment, along with contractures of the knee due to prolonged immobilization, have traditionally plagued the orthopedist's management of patients who have these injuries^{3,4}.

1.1 Aim

“Functional outcome of closed intramedullary interlocking nailing in Gustillo-Anderson type I and II compound fractures of femoral shaft”.

1.2 Materials

The present prospective observational study was conducted at the Department of

Orthopaedics of a Medical College and tertiary care centre prospective during the period of June 2013 to May 2015 (2 years).

A total of 20 Patients with Gustillo-Anderson Type I and II Open Fractures of Femoral Shaft, satisfying inclusion and exclusion criteria were included in the study after taking informed consent.

1.3 Inclusion Criteria

Age 18-70 years.

Gustillo Anderson Class I and II fractures.

1.4 Exclusion Criteria

Critically injured Patients.

Patient age less than 18 years and above 70 years.

Patients who refused to participate in study.

1.5 Results

Excellent or good functional outcome as per Harris Hip score was observed in 80% cases while fair results were observed in 15% cases. One case with deep wound infection and non union showed poor outcome.

Table 1. Distribution of subjects based on functional outcome

Outcome (Harris Hip Score)	N	%
Excellent	12	60.0%
Good	4	20.0%
Fair	3	15.0%
Poor	1	5.0%
Total	20	100.0%

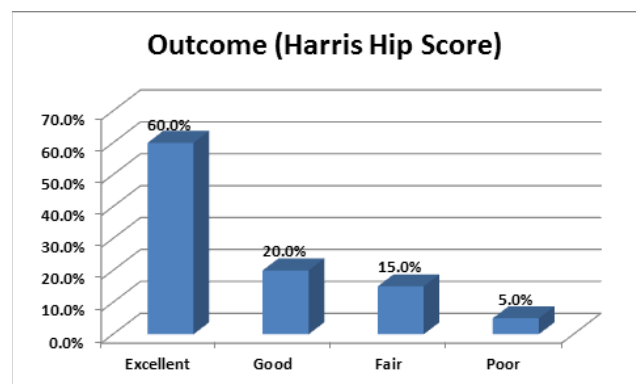


Figure 1.

2. Discussion

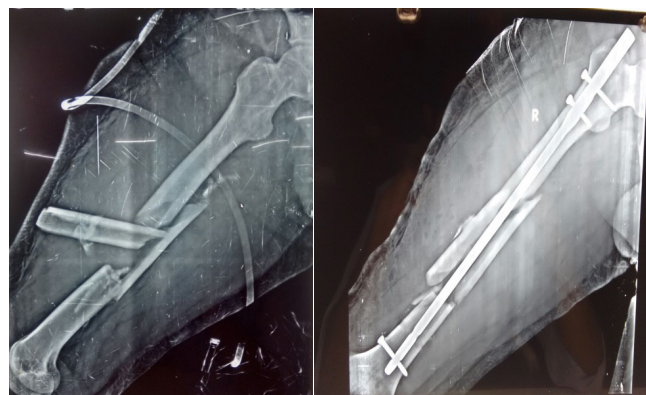
The present prospective observational study was conducted with the aim of studying functional outcome of closed intramedullary interlocking nailing among patients with Gustillo-Anderson type I and II open fractures of femoral shaft during the period of June 2013 to May 2015 (2 years).

Interlocked intramedullary nailing system showed excellent result in both close and open fractures. Surgery was done by same orthopaedic surgeon. Primary closure of all wounds was done after debridement. Definitive treatment was done after 3-4 days. A shorter operative time, less blood loss, easy operative technique, early mobilization, shorter hospital stay and lesser post operative problems, where ever facilities for inter locked nailing became available, most orthopedic surgeons started treating fractures shaft of femur by interlocked nailing because these system control shortening, angulation and rotation in complex fractures via locking screw⁵⁻⁷.

Average hospital stay was 5-7 days, with broad spectrum antibiotic given for 3 days.

Post-op protocol followed was same for all patients. Pt was mobilized on day 2 with CPM on day 2 till 90°. Full Flexion was achieved within a week. Stitches were removed on 10th day.

Case 1:



PRE-OP

POST-OP

Type	Description
I	Skin wound less than 1 cm Clean Simple fracture pattern
II	Skin wound more than 1 cm Soft-tissue damage not extensive No flaps or avulsions Simple fracture pattern
III	High-energy injury involving extensive soft-tissue damage Or multifragmentary fracture, segmental fractures, or bone loss irrespective of the size of skin wound Or severe crush injuries Or vascular injury requiring repair Or severe contamination including farmyard injuries

Gustilo and Anderson classification of open fractures

2.1 Socio-Demographic Profile

Most of the study subjects were between 21-40 years of age with mean age of 31.6 years. Out of total 20 subjects, 16 were males with a male to female ration of 4:1. Most common mode of injury was road traffic accident (70%) followed by fall (15%).

In a similar study by Mohammad AK, et al., there were 17 males and 3 female patients with male to female ratio 5.8:1. there were 12 patients in age group 20-29, 4 in 30-39, 2 each in age group 40-49 and 50-59. Mean age was 30.6 years in male and 32.5 years in female. The most common mode of injury was RTA (75%) followed by gunshot

wound⁷. Similar demographic pattern was also observed by Ferracini AM et al.,⁸ and Malik ZU et al., who observed the male to female ratio of 4:1 and 7:1 respectively⁹.

2.2 Fracture Union

Most cases had fracture union by 6th month with mean fracture union time of 19.6 +/- 2.9 weeks. Mean fracture union time in type I and II fractures was 19.2 and 20.1 weeks respectively. The difference was not statistically significant (p-0.31).

Mohammad AK et al., in their study found that most of the fractures took about 18 weeks to heal (60%) while some 5%-10% healed little earlier. Fracture healing time as observed by other authors is as follows:

Table 2. Comparison of fracture healing time of the present study with other studies

Studies	Time of Union (weeks)
Jhonson et al.	13.8
Kempf et al.	17
Jhonson& Greenberg et al.	14
Christie et al.	17
Sojbjerg et al.	12
Wiss et al.	32
Anastopolus et al.	18
Hajek et al.	12
Mahmood et al.	32
Kropfl et al.	14
Baixuli et al.	20
Present study	19.6

3. Complications

Complications were present in 4 cases (20%). Superficial wound infections were present in 3 cases (15%) while deep wound infection was present in 1 case (5%).

Open femoral shaft fractures are serious injuries presupposing a higher complications rate following treatment, which may range from 0 to 24%¹⁰⁻¹². In our study we found general complications in 20% cases, which is close to the rates found by other authors¹⁰⁻¹³.

Infection is the most feared condition in open fractures - may present rates ranging from 0 to 16 %¹³⁻¹⁶. Riemer et al., discussed the results of 141 femoral fractures treated with plates, including 63 open fractures, with an infection rate of 10.2%. O'Brien et al., studied 63 open femoral fractures primarily treated with intramedullary locked milled nail with an infection rate of 12%. The global infection rate is 16.2%. In a study by Malik ZU et al., out of total 16 fractures, 15 (94%) united within 6 months and one fracture had delayed union. Two patients had

superficial wound infection and one patient had deep infection.

One patient with deep infection, in our study, evolved with union failure and was submitted to new debridement procedures and antibiotics therapy. After the infection was cured, the nail was removed. Superficial infections (3 cases) were definitively treated with antibiotic therapy. Delayed Union was found in two cases with superficial infection. One fracture with delayed union evolved to cure after treating the superficial infection. These rates are consistent to the ones described by literature.

At the end of the treatment, Knee Flexion < 100°, Ext. Rotation of Femur < 20°, and Femur Shortening >1 cm was observed in one case each respectively. In a study by Mohammad et al., there were total of 3 (15%) postoperative complications with one each: Knee flexion < 100°, external rotation and shortening of the femur of 20° and 2 cm respectively.

3.1 Functional Outcome

Excellent or good functional outcome as per Harris Hip score was observed in 80% cases while fair results were observed in 15% cases. One case with deep wound infection and non union showed poor outcome.

Similar success rates were reported in other series, with both open and close fractures included¹⁷⁻¹⁹. In a similar study by Ferracini et al., good to excellent outcomes were found in 28 fractures (75.7%), fair (7.5%) in three cases, and poor (15%) in six [20]. Malik et al., also reported 94% good to excellent results. Ferracini et al., found that mean time for union according to Gustilo's classification, for type I, was 20.29 ± 2.9 weeks and for type II, it was 21.7 ± 2.2²⁰

Thus we can conclude that interlocked intramedullary nailing of open femoral shaft fracture is a gold standard method of treatment with advantages of predictability, low rate of complications and full weight bearing is significantly earlier.

4. Summary and Conclusion

The present prospective observational study was conducted at the Department of Orthopedics of a Medical College and tertiary care centre during the period of June 2013 to May 2015 (2 years). The aim of the study was to study the functional outcome of closed intramedullary interlocking nailing among patients with Gustillo-Anderson type I and II open fractures of femoral shaft. A total of 20 consecutive patients satisfying inclusion and exclusion criteria were included in the study after taking informed consent. A detailed clinical history of all the

patients was taken along with thorough general, local and systemic examination. After undergoing primary closed intramedullary interlocking nailing of fracture femoral shaft as per standard hospital protocol, the patients were assessed for functional outcome using Harris Hip score. Following observations were made during the study:

- Most of the study subjects were between 21-40 years of age with mean age of 31.6 years.
- Out of total 20 subjects, 16 were males with a male to female ration of 4:1.
- Most common mode of injury was road traffic accident (70%) followed by fall (15%).
- Out of total 20 cases, 13 had fractures of right side while remaining 7 had left sided fractures.
- According to Gustillo Anderson Classification, 65% fractures were of type I while remaining 35% cases were of class II.
- A total of 7 patients (35%) had concomitant injuries. Five out of seven had injuries on extremities while 1 case each had head and chest injury.
- Co-morbidities like diabetes and hypertension was observed in one fourth of the cases.
- Most cases had fracture union by 6th month with mean fracture union time of 19.6 +/- 2.9 weeks.
- Mean fracture union time in type I and II fractures was 19.2 and 20.1 weeks respectively. The difference was not statistically significant (p-0.31).
- Complications were present in 4 cases (20%). Superficial wound infections were present in 3 cases, out of which delayed union was observed in 2 cases. Deep wound infection was present in one case that ends up with non union of fracture.
- Knee Flexion < 100°, Ext. Rotation of Femur < 20°, and Femur Shortening >1 cm was observed in one case each respectively.
- Excellent or good functional outcome as per Harris Hip score was observed in 80% cases while fair results were observed in 15% cases. One case with deep wound infection and non union showed poor outcome.

We thus conclude that closed intramedullary interlocking nailing is a safe and effective treatment for open fractures of shaft of femur with higher rate of excellent and good results. Other advantages includes low rate of complications and significantly early full weight bearing.

5. References

1. Rudloff MI. Campbell's operative orthopaedics. 12th ed. Elsevier; 2013. P. 2702-18.
2. Salmineen ST, Philajamaki HK, Avikainen VJ, Bostman OM. Population based epidemiologic and morphologic study of femoral shaft fractures. *Clin Orthop Relat Res.* 2000; 372:241-9.
3. Buchholz RW, Jones A. Current concepts review fractures of the shaft of the femur. *J Bone Joint Surg.* 1991; 10(73A):1561-6.
4. Winqvist RA, Hansen ST. Comminuted fractures of the femoral shaft treated by intramedullary nailing. *Orthopclin North Am.* 1980; 11(3):633-48.
5. Russell TA, Taylor JC, Lavelle DG, Beals NB, Brumfied DC, Durham AG. Mechanical characterization of femoral interlocking intramedullary nailing interlocked nailing for treatment of segmental fractures of the femur. *J Bone joint Surg.* 1990; 72A(5):724-8.
6. Russell TA. Biomechanical concepts of femoral intramedullary nailing (Review paper). *Intern J orthop Trauma.* 1991; 1(1):36-51
7. Mohammad AK, et al. Comminuted femoral shaft fracture and intramedullary nailing. *Journal of Nobel Medical College.* 2012; 1(2):48-52.
8. Malik ZU, Hanif MS, Safdar A, Masood T. Planned external fixation to locked intramedullary nailing conversion for open fractures of shaft of femur and tibia. *J Coll Physicians Surg Pak.* 2005; 15(3):133-6.
9. Farracini AM, et al. Prospective and randomised study of patients with open fractures of the femoral shaft, treated with plate or open intramedullary locked nail. *Actaortop Bras.* 2008; 16(2).
10. Green A, Trafton PG. Early complications in the management of open femur fractures: A retrospective study. *J Orthop Trauma.* 1991; 5:51-6.
11. Noumi T, Yokoyama K, Ohtsuka H, Nakamura K, Itoman M. Intramedullary nailing for open fractures of the femoral shaft: Evaluation of contributing factors on deep infection and nonunion using multivariate analysis. *Injury.* 2005; 36:1085-93.
12. Williams MM, Askins V, Hinkes EW, Zych GA. Primary reamed intramedullary nailing of open femoral shaft fractures. *Clin Orthop Relat Res.* 1995; (318):182-90.
13. O'Brien PJ, Meek RN, Powell JN, Blachut PA. Primary intramedullary nailing of open femoral shaft fractures. *J Trauma.* 1991; 31:113-6.
14. Fernandes HJA. Placaemponte e haste intramedularbloqueada: Estudocomparativo no tratamento das fraturas-multifragmentárias da diáfise do fêmur [tese]. São Paulo: Universidade Federal de São Paulo; 2000.
15. Van Riemer JLM, Schoots FJ. Femoral shaft fractures treated with plate fixation and interlocked nailing. A comparative retrospective study. *Injury.* 1992; 23:219-22.
16. Vasconcelos JW, Morais SV, Porto LCK, Santos RJM. Tratamento das fraturascominutivas do fêmur com utilização da placaemponte. *Rev Bras Ortop.* 2004; 39:415-22.
17. Grosse A, Christie J, Taglang G, Court-Brown C, McQueen M. Open adult femoral shaft fracture treated by early intramedullary nailing. *J Bone Joint Surg Br.* 1993; 75:562-5.
18. Fernandes HJA. Placaemponte e haste intramedularbloqueada: Estudocomparativo no tratamento das fraturas-multifragmentárias da diáfise do fêmur [tese]. São Paulo: Universidade Federal de São Paulo; 2000.

- queada: Estudocomparativo no tratamento das fraturas-multifragmentárias da diáfise do fêmur [tese]. São Paulo: Universidade Federal de São Paulo; 2000.
19. Van Niekerk JLM, Schoots FJ. Femoral shaft fractures treated with plate fixation and interlocked nailing. A comparative retrospective study. *Injury*. 1992; 23:219–22.
 20. Ferracini AM, Faloppa F, Daltro GC, Crisóstomo DC Jr, Reis FB, Belotti JC. Prospective and randomized study of patients with open fractures of the femoral shaft, treated with plate or open intramedullary locked nail. *ActaOrtop Bras*. 2008; 16(2).