

# Magnetic Resonance Imaging Evaluation of Various Neoplastic Lesions of Ankle and Foot at a Tertiary Health Care Centre

Prerit J. Sharma<sup>1\*</sup>, Priti Komatwar<sup>2</sup> and Arvind K. Takle<sup>3</sup>

<sup>1</sup>Former Resident, Department of Radio-Diagnosis, Dr. Vasant Rao Pawar Medical College, Hospital and Research Centre, Nashik – 422003, Maharashtra, India; Sharma.prerit@rocketmail.com

<sup>2</sup>Former Resident, Department of Radio-Diagnosis, Dr. Vasant Rao Pawar Medical College, Hospital and Research Centre, Nashik – 422003, Maharashtra, India

<sup>3</sup>Professor, Department of Radio-Diagnosis, Dr. Vasant Rao Pawar Medical College, Hospital and Research Centre, Nashik – 422003, Maharashtra, India

## Abstract

**Introduction:** Magnetic Resonance (MR) Imaging has opened new horizons in the diagnosis and treatment of many musculoskeletal diseases of the ankle and foot and is useful to confirm the presence and extent of a soft tissue mass and to determine the precise anatomic location, which aids in surgery; in some cases, the appearance is specific for a particular lesion. **Purpose of Study:** Our aim was to study various Magnetic Resonance Imaging findings of various neoplastic lesions of ankle and foot. **Results:** Total 49 patients (Male - 27, Female - 22) were studied with various neoplastic conditions involving the ankle and foot. Amongst the neoplastic lesions involving the bones, 62.5% of neoplasms were benign lesions while 37.5% were malignant. Amongst the neoplastic lesions involving the soft tissue, 36.7% of neoplasms were benign lesions while 63.3% were malignant. On MRI, 84% of study population with neoplastic lesions showed hyperintense signal on T1WI while 16% showed hypointense signal. Although 26.7% of study population with neoplastic lesions showed hypointense signal on T2WI, while 73.3% showed hyperintense signal. **Conclusion:** According to our study, MRI in combination with other radiologic images is very helpful in appropriate diagnostic imaging for neoplastic lesions involving the bone and soft tissue of the ankle and foot.

**Keywords:** Ankle Pathologies, Foot Pathologies, MRI, Neoplastic

## 1. Introduction

Magnetic Resonance (MR) Imaging has opened new horizons in the diagnosis and treatment of many musculoskeletal diseases of the ankle and foot. It demonstrates abnormalities in the bones and soft tissues before they become evident with other imaging modalities. The exquisite soft-tissue contrast resolution, non-invasive nature and multiplanar capabilities of MR imaging make it especially valuable for the detection and assessment of a variety of soft-tissue disorders of the ligaments, tendons and other soft-tissue structures. In 2003, Paul C.

Lauterber and Peter Mansfield won the Nobel Prize for their discovery of using MRI as a diagnostic tool<sup>1</sup>.

A few tumors of bone have a predilection for the foot and ankle, but malignant primary and metastatic lesions are rare in the foot and ankle. It is also useful to confirm the presence and extent of a soft tissue mass and to determine the precise anatomic location, which aids in surgery; in some cases, the appearance is specific for a particular lesion.

MRI in combination with other radiologic images is currently regarded as the most appropriate diagnostic imaging for benign bone and soft tissue lesions.

Therefore, we conducted this study to evaluate various Magnetic Resonance Imaging findings of ankle and foot pathologies.

## 2. Aim and Objective

To study various Magnetic Resonance Imaging findings of various neoplastic lesions of ankle and foot.

## 3. Materials and Methods

- **Type of Study:** This is a Descriptive study.
- **Study Period:** JAN 2017 – OCT 2018 (22 Months).
- **Study Setting:** The study will be conducted in MRI section of Department Radio-diagnosis of Medical College and Tertiary Health Care Centre.
- **Study Participants:** Sample size: 49 cases.

Formula used for calculation of the sample size:  
 $n^0 = Z^2pq/e^2$

- Where  $n^0$  is the sample size,  $Z^2$  is the abscissa of the normal curve that cuts off an area  $\alpha$  at the tails ( $1-\alpha$  equals the desired confidence level is 95%),  $e$  is the desired level of precision,  $p$  is the estimated proportion of an attribute that is present in the population, and  $q$  is  $1-p$ .

### 3.1 Inclusion Criteria

All patients referred to the MRI section of the Department of Radio Diagnosis of Medical College and Research Center for evaluation of any suspected pathology of ankle or foot, irrespective of age and sex.

### 3.2 Exclusion Criteria

Any patient with contraindication to MRI i.e. patients with ferro magnetic implants, claustrophobia etc.

## 4. Methodology

This study was conducted in MRI section of Department of Radio-diagnosis of Medical College and Tertiary Health Care Centre. A total of 49 patients were included after satisfying the eligibility criteria. Written informed consent was taken from all study participants. The patients having any suspected ankle or foot pathologies were subjected to MRI of ankle or foot respectively. Siemens Magnetom Essenza 1.5 TESLA machine was used for the

study. T1WI, T2WI, PD, STIR, fat suppression sequences in coronal, sagittal and axial sections were taken. The bio data, detailed clinical history and MRI findings were noted in pre-designed proforma (Annexure I).

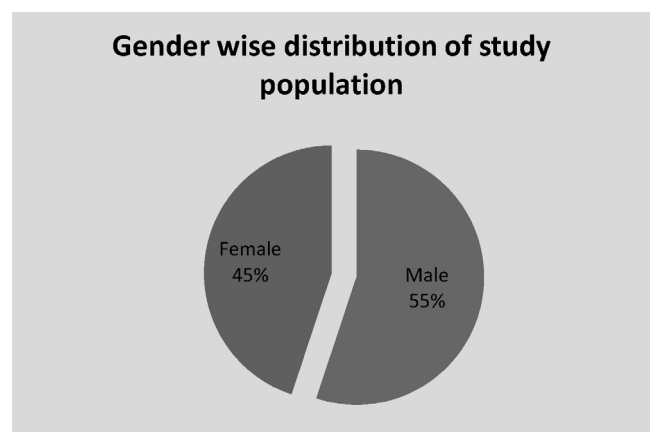
### 4.1 Statistical Analysis

All the collected data was entered in Microsoft Excel sheet and then transferred to SPSS software ver. 17 for analysis. Qualitative data was presented as frequency and percentages and analyzed using chi-square test. Quantitative data was presented as mean and SD and compared by t-test. Correlation between variables was done by using Pearson's correlation test. P-value < 0.05 was taken as level of significance.

## 5. Results

- Total 49 patients (Male - 27, Female - 22, distribution as shown in chart 1) were studied with various neoplastic conditions.
- In neoplastic lesions, soft tissue lesions were more commonly seen (61.2%) as compared to osseous lesions (32.6%), while both soft tissue and osseous involvement was seen in 6.2% of the study population (distribution as shown in Table 1).
- Amongst the neoplastic lesions involving the bones 62.5% of neoplasms were benign lesions while 37.5% were malignant (distribution as shown in Table 2).
- Amongst the neoplastic lesions involving the soft tissue 36.7% of neoplasms were benign lesions while 63.3% were malignant (distribution as shown in Table 3).
- On MRI, 84% of study population with neoplastic lesions showed hyperintense signal on T1WI while

**Chart 1.** Gender wise distribution of patients



16% showed hyperintense signal. Although 26.7% of study population with neoplastic lesions showed hypointense signal on T2WI, while 73.3% showed hyperintense signal (distribution as shown in Tables 4 and 5).

**Table 1.** Distribution of the neoplastic lesions depending on the involvement

Types of lesions	No of patients	Percentage (%)
Bone	16	32.6%
Soft Tissue	30	61.2%
Both	3	6.2%
Total	49	100%

**Table 2.** Type of neoplastic lesions involving bone amongst study population

Neoplastic lesions of bone	Number of patients	Percentage (%)
Benign	10	62.5%
Malignant	6	37.5%
Total	16	100.00%

**Table 3.** Type of neoplastic lesions involving soft tissue amongst study population

Neoplastic lesions of soft tissue	Number of patients	Percentage (%)
Benign	11	36.7%
Malignant	19	63.3%
Total	30	100%

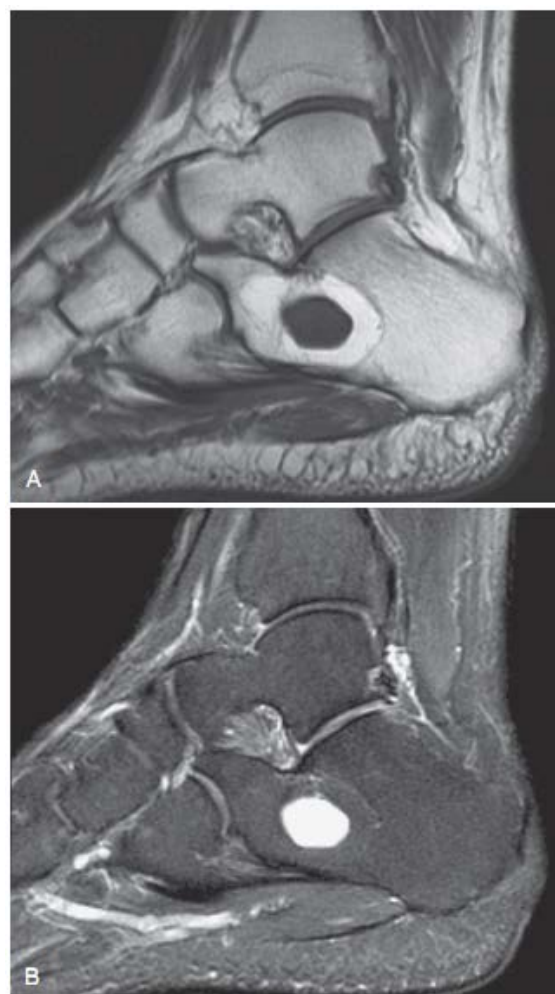
**Table 4.** Appearance of various neoplastic lesions on T1WI amongst study population

On T1WI	Frequency	Percentage (%)
Hypointense	41	84%
Hyperintense	8	16%
Total	49	100.0%

**Table 5.** Appearance of various neoplastic lesions on T2WI amongst study population

On T2WI	Frequency	Percentage (%)
Hypointense	13	26.7%
Hyperintense	36	73.3%
Total	49	100.0%

## Representative Images from the Cases

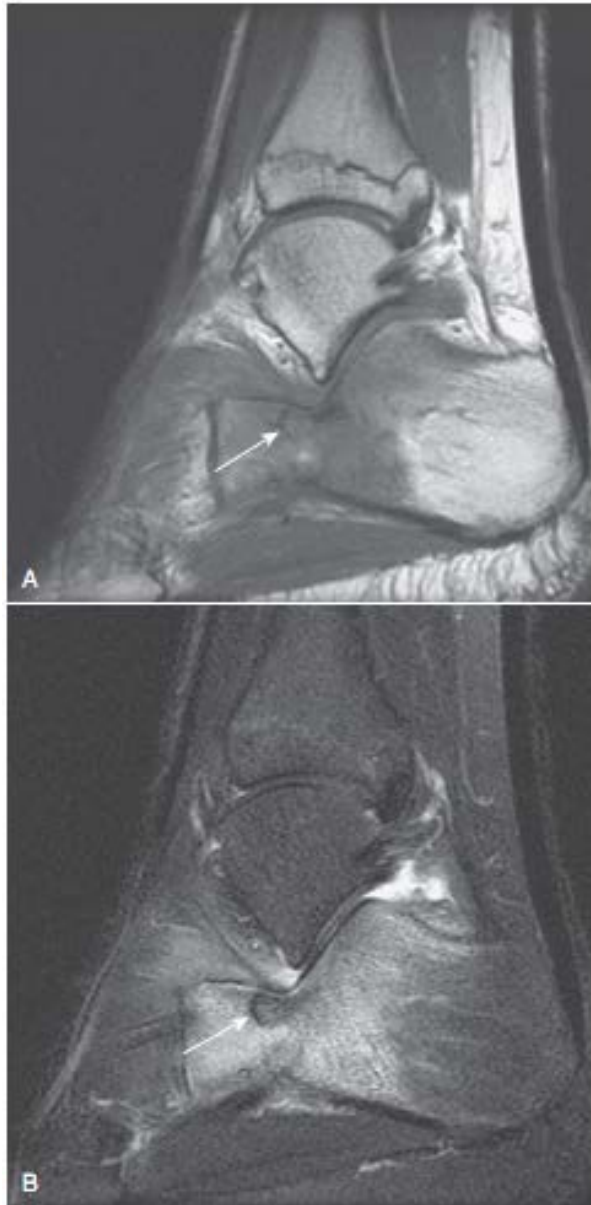
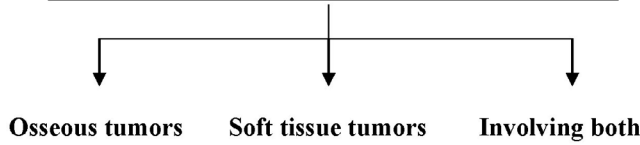


**Figure 1.** Unicameral bone cyst; **Figure A** - T1W sagittal image of the hind foot. There is a round, high signal fat mass in the neck of the calcaneus that is well circumscribed. In the center of this fatty mass is a focus of low signal. **Figure B** - FSE-T2W sagittal image of the hind foot. The low signal focus on T1W is fluid-bright on T2W and represents the remaining fluid in a resolving unicameral bone cyst. The periphery has resolved into normal marrow.

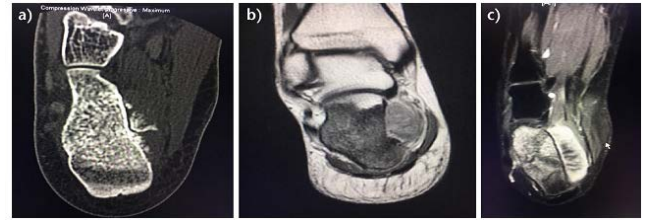
## 6. Discussion

A few tumors of bone have a predilection for the foot and ankle, but malignant primary and metastatic lesions are rare in the foot and ankle. MRI generally does not add to our ability to make the diagnosis, but is useful for showing the extent of disease within the bone and for assessing for any soft tissue component.

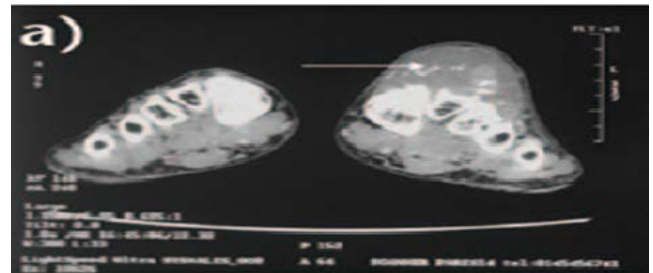
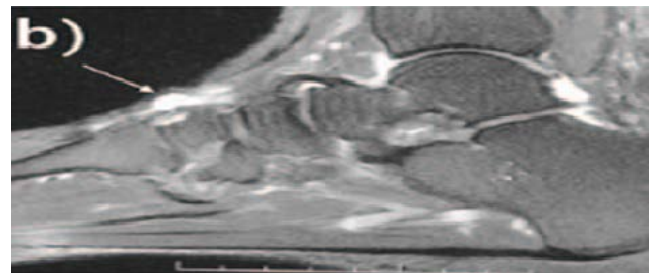
**NEOPLASTIC LESIONS OF ANKLE AND FOOT**



**Figure 2.** Osteoid osteoma; **Figure A** - T1W sagittal image of the ankle. There is a large amount of low signal in the anterior half of the calcaneus, which is edema from an osteoid osteoma. The nidus is seen adjacent to the sinus tarsi (arrow). **Figure B** - FSE-T2W sagittal image of the ankle. The edema in the calcaneus is seen as increased signal, and the nidus of the osteoid osteoma is low signal (arrow).



**Figure 3.** Osteosarcoma of the calcaneus in a 17-year-old female. **Figure A** - CT scan showed increased bone density of the calcaneus and a soft tissue extension with periosteal reaction. **Figure B** - MRI showing a low signal in bone and soft tissue extension on T1 coronal view. **Figure C** - Intense tumor enhancement on T2 fat sat injected sequences.



**Figure 4.** This 55-year-old male had resection of a large tumour of the dorsum of the foot without biopsy. The histological diagnosis was **Grade 2 Chondrosarcoma**. **Figure A** - CT scan of the left foot before first surgery. **Figure B** - MRI at time of local recurrence.

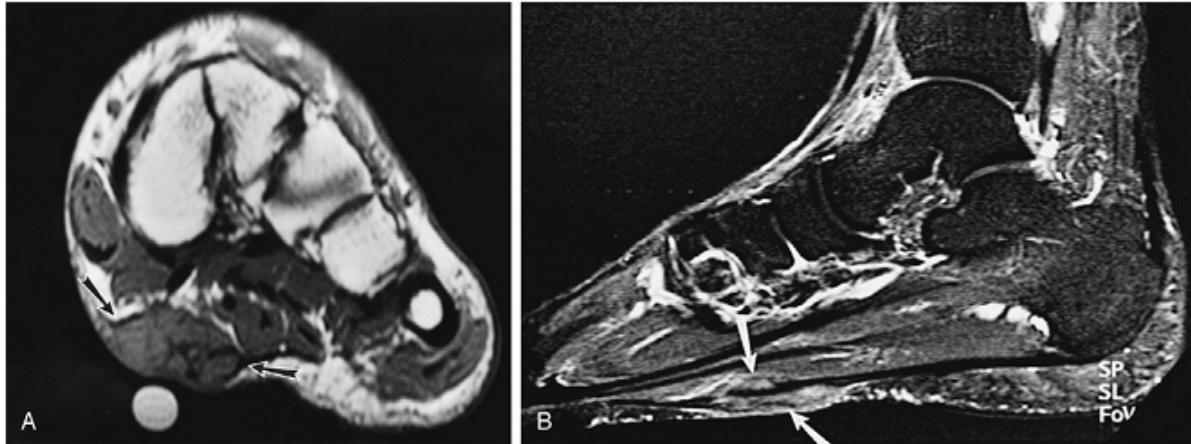
## 6.1 Osseous Tumors

### 6.1.1 Unicameral Bone Cyst

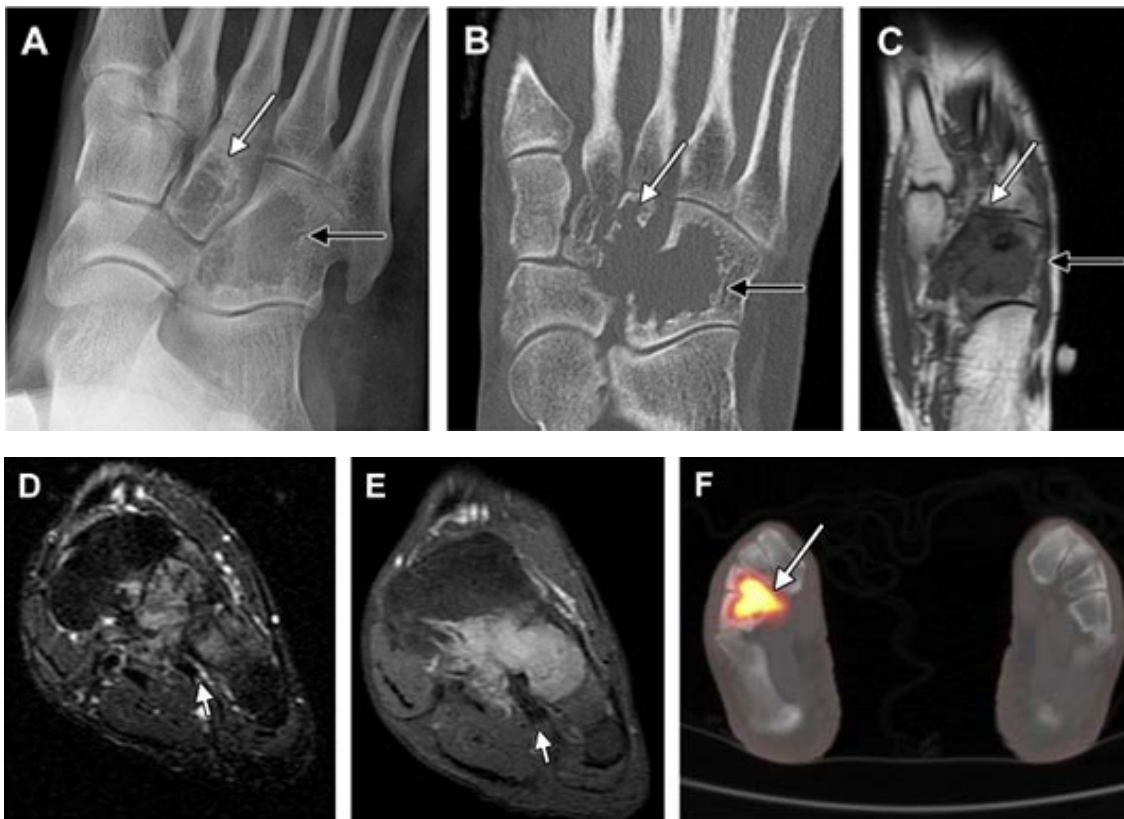
The calcaneus is a common site for simple bone cysts (unicameral bone cyst), occurring in the mid portion or neck of the calcaneus.

### 6.1.2 Osteoid Osteoma

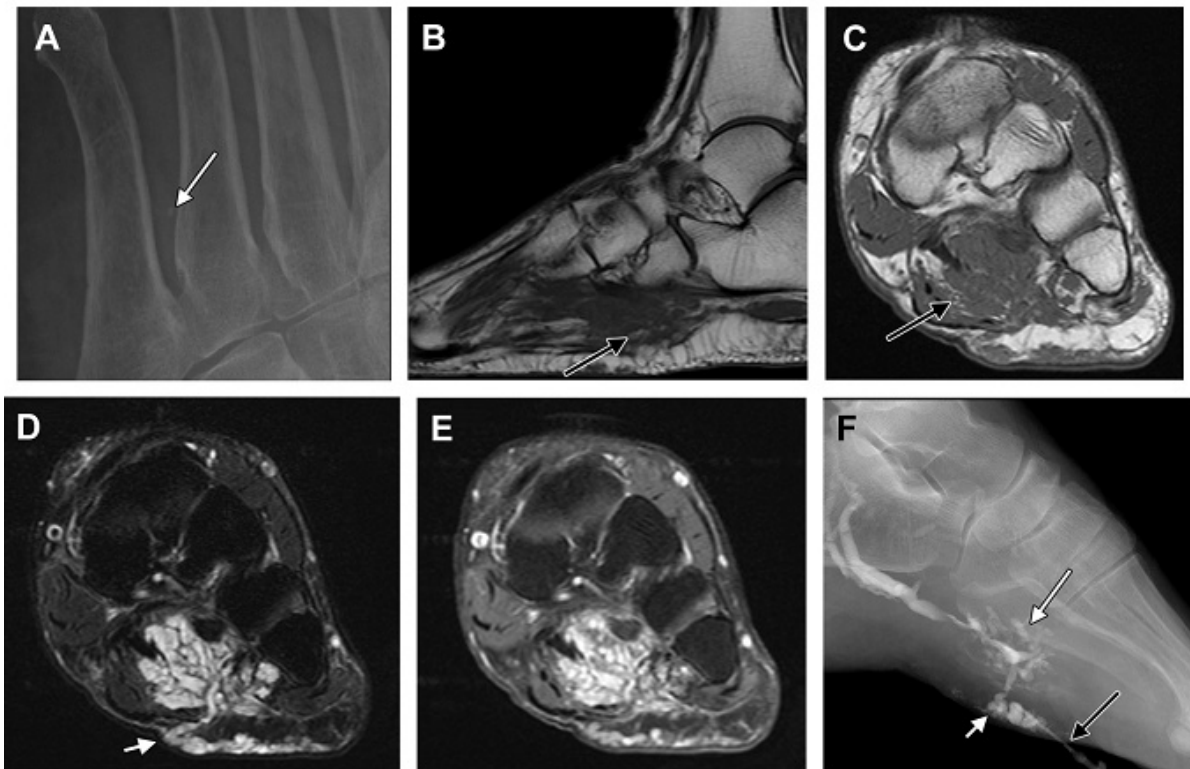
The talus and calcaneus are sites of predilection for osteoid osteomas, which produce periosteal reaction and may show extensive bone marrow edema and edema in the surrounding soft tissues on MRI.



**Figure 5.** Plantar fibromatosis; **Figure A** - T1W short-axis axial image of the mid foot. There is an intermediate signal mass (arrows) surrounding the plantar fascia. **Figure B** - STIR sagittal image of the foot. The mass (arrows) is heterogeneous, but generally remains low signal. The plantar fascia courses through the center of the mass.



**Figure 6.** Tenosynovial GCT in a 51-year-old woman with a 9-month history of foot pain; **Figure A** - Oblique radiograph shows well-defined lesions in the cuboid (black arrow) and lateral cuneiform (white arrow). **Figure B** - CT suggests that the lesions in the cuboid (black arrow) and lateral cuneiform (white arrow) are the result of extrinsic erosion by an articular or para-articular process. **Figure C** - Long-axis T1-WI shows a low-signal lesion involving the cuboid (black arrow) and lateral cuneiform (white arrow), related to hemorrhage. Short-axis inversion recovery. **Figure D** - and post-contrast T1-WI with FS. **Figure E** - Images show the peroneus longus tendon (arrows) passing through the soft tissue lesion. The plantar aspect of the soft tissue mass has an infiltrative appearance. **Figure F** - Axial fused image from FDG PET/CT shows intense metabolic activity (arrow) in the right foot mass.



**Figure 7.** Venous malformation in the foot of a 49-year-old woman with a left foot mass since childhood, now enlarging and painful; **Figure A** - Oblique radiograph shows mild demineralization of the bones and a small phlebolith (arrow). **Figure B** - Sagittal T1-WI shows atrophy of the plantar muscles with increased intramuscular fat (arrow). **Figure C** - Short-axis T1-WI shows atrophy of the plantar muscles with increased intramuscular fat (arrow). **Figure D** - Short-axis T2-WI with FS shows a large vein (arrow) draining into the lobulated, septated lesion. The lesion does not respect tissue planes and extends along the fascia, between tendons, and within muscle. **Figure E** - Short-axis delayed post-contrast T1-WI with FS shows pooling of contrast within the lobulated, septated mass. **Figure F** - Venogram obtained before sclerotherapy shows the injection needle (black arrow) in the vein indicated in panel.

## 6.2 Enchondroma

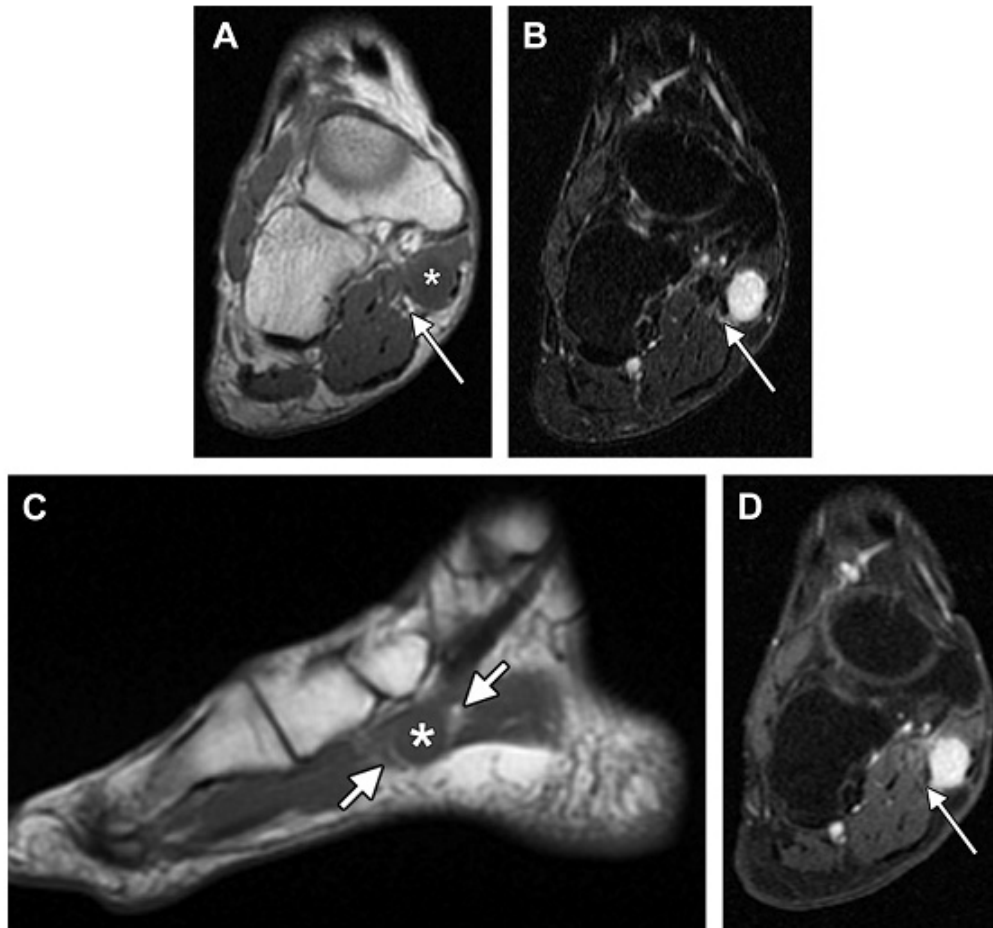
Enchondromas are relatively common, accounting for 10%–25% of all benign bone tumors. The true incidence is actually much higher since many tumors are detected incidentally and never biopsied. They appear between the 2<sup>nd</sup> and 4<sup>th</sup> decades of life although they have wide age distribution and both sexes being equally affected. They may be solitary or multiple. Later benign commonly associated with syndrome like Ollier's disease and Maffucci syndrome<sup>2</sup>. Most enchondromas in a surgical series consist of lesions involving the small bones of the hands and feet with pain being the most common complaint. Enchondromas of larger bones may be incidental findings on radiography<sup>3</sup>. Based on the appearance on X-ray, Takigawa<sup>4</sup> classifies as: Central

(58%), eccentric (19%), combined (21%), polycentric (11%) and giant enchondroma (3%).

Diagnosis is often suggested by radiology which usually demonstrates a small (<5 cm) cartilaginous lesion with intramedullary calcifications without cortical involvement or soft-tissue extension. However, radiologically enchondromas can be difficult to differentiate low-grade chondrosarcoma, epidermoid cyst, osteomyelitis, bone cyst as was in our cases<sup>5</sup>. Occasionally, an enchondroma will recur many years later and rarely, recur as a low-grade chondrosarcoma<sup>6</sup>.

## 6.3 Osteochondroma

An osteochondroma is a hyaline cartilage capped protrusion on the external surface of a bone. Osteochondromas are the most common primary bone



**Figure 8.** Schwannoma in a 56-year-old woman with a 6-month history of medial foot pain; **Figure A** - Short-axis T1-WI and **Figure B** - short tau inversion recovery images through the midfoot show a low to intermediate T1-weighted and intensely hyperintense T2-weighted mass (asterisk) located within the abductor hallucis muscle. The medial plantar nerve (arrows) is not involved, and no target sign is identified. **Figure C** - Sagittal T1-WI shows the low to intermediate signal mass (asterisk) surrounded by caps of fat (arrows), indicating slow growth. **Figure D** - Short-axis post contrast T1-WI with FS shows avid lesion enhancement mass and no involvement of medial plantar nerve (arrow).

tumors and account for approximately 50% of all benign bone tumors.

#### 6.4 Aneurysmal Bone Cyst

An Aneurysmal Bone Cyst (ABC) is a benign, locally destructive lesion of the bone, occurring as a primary bone cyst in ~79% of cases or as a secondary lesion arising from other osseous conditions in ~20% of cases<sup>7-9</sup>.

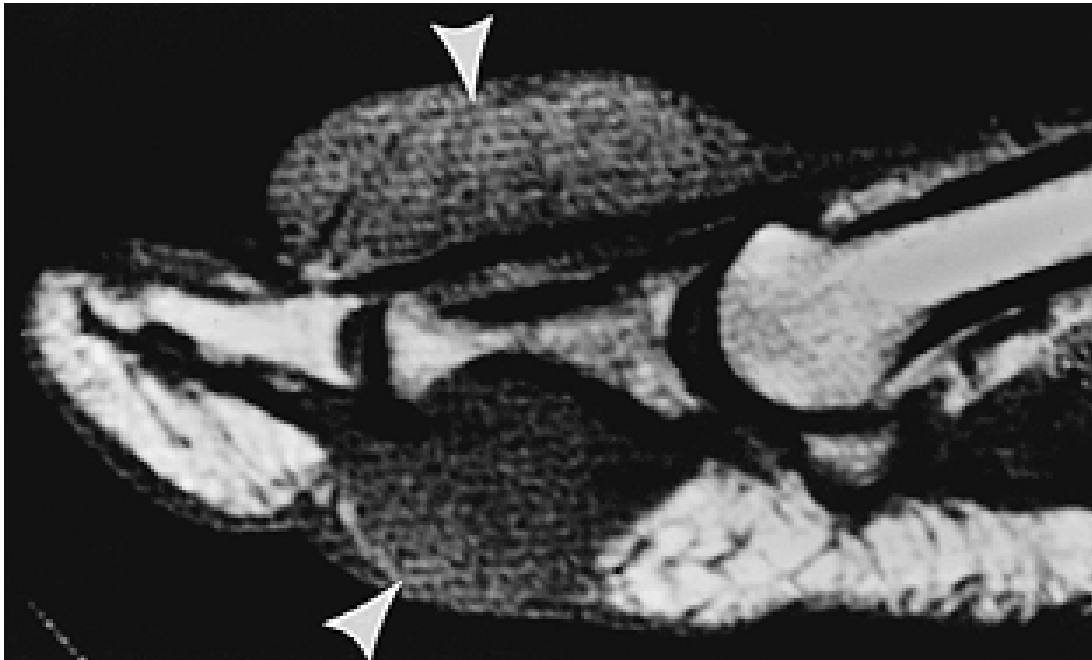
Computed tomography and MRI scans may be helpful in the diagnosis of ABC, since T2-weighted MRI could detect a deformity in the involved metatarsal bone as a segmented, expansile, multiseptated lesion with a large quantity of fluid present<sup>10</sup>.

#### 6.5 Osteosarcoma

Osteosarcoma is a malignant tumor forming neoplastic bone matrix which rarely occurs in the foot (1% of all osteosarcoma) and is only slightly less uncommon at the distal tibia or fibula (2.5%). On MRI, the ossified matrix will be seen as a low signal on all pulse sequences while the soft-tissue tumour can be heterogeneous with varying signal intensity and enhancement depending on the degree of haemorrhage and necrosis<sup>11,12</sup>.

#### 6.6 Ewing's Sarcoma

Ewing's sarcoma is a small round-cell tumor of bone and soft tissue with neuro-ectodermal differentiation that can



**Figure 9.** Synovial sarcoma; T1W sagittal image of the great toe. A large, intermediate signal mass (*arrowheads*) surrounds the great toe. This is a nonspecific MRI appearance, but was found to be a synovial sarcoma at surgery.

involve any part of the skeleton. It occurs rarely in the foot, but is the most common malignancy of feet bones in children<sup>13</sup>.

### 6.7 Chondrosarcoma

Endosteal scalloping of the cortex and cortical destruction with a soft tissue mass are characteristic of a malignant lesion. There is rarely a sclerotic rim and periosteal reaction is rare. On MRI scanning, the soft-tissue extension, hyper-intense in T2, appears more lobulated and thicker than in benign enchondromata. Scalloping is usually not visible in small bones of the foot<sup>12,14,15</sup>.

## 7. Soft Tissue Tumors

### 7.1 Plantar Fibromatosis

Plantar fibromatosis is a benign proliferation of fibrous tissue along the plantar aspect of the foot arising in the plantar fascia. These lesions often, although not invariably, enhance with intravenous gadolinium. The upper margin may be infiltrative and can grow into the deeper compartments of the foot, whereas the lower margin usually is well defined and outlined by the subcutaneous fat<sup>16</sup>.

### 7.2 Tenosynovial Giant Cell Tumour

Tenosynovial GCT (TGCT) is divided into 2 forms: Localized and diffuse. The localized form is also known as localized GCT of tendon sheath, whereas the diffuse form is also known as Pigmented Villonodular Synovitis (PVNS)<sup>16</sup>.

## 8. Vascular Anomalies - (Hemangiomas and Epithelioid Hemangioendothelioma)

There is much confusion in the terminology of vascular anomalies. The most widely accepted classification scheme is based on the degree of cellular proliferation and divides vascular anomalies into neoplasms and malformations<sup>17</sup>.

### 8.1 Synovial Sarcoma

The most common malignant soft tissue tumor of the foot is the synovial sarcoma. Necrosis and hemorrhage may be present and cause a heterogeneous appearance after gadolinium administration.



## 9. Other Sarcomas

Liposarcoma and malignant fibrous histiocytoma are rare below the knee, but if they do occur in the foot/ankle region, they tend to be present at the ankle.

## 10. Conclusion

In summary, MRI in combination with other radiologic images is very helpful in appropriate diagnostic imaging for neoplastic lesions involving the bone and soft tissue of the ankle and foot.

## 11. References

- Lauterbur PC. Nobel Lecture. All science is interdisciplinary- from magnetic moments to molecules to men. *Biosci Rep.* 2004 Jun; 24(3): 165–78. PMID: 16209126. <https://doi.org/10.1007/s10540-005-2578-1>
- Lucas DR, Bridge JR. Chondromas: Enchondroma, periosteal chondroma and enchondromatosis. Fletcher CD, Unni KK, Fredrik M, editors. *Pathology and Genetics of Tumors of Soft Tissue and Bone (WHO)*. 4th ed. Lyon: IARC Press; 2002. p. 237–40.
- Lichtenstein L, Goldman RL. Cartilage tumors in soft tissues, particularly in the hand and foot. *Cancer.* 1964; 17: 1203–8. [https://doi.org/10.1002/1097-0142\(196409\)17:9<1203::AID-CNCR2820170917>3.0.CO;2-7](https://doi.org/10.1002/1097-0142(196409)17:9<1203::AID-CNCR2820170917>3.0.CO;2-7)
- Fernández JM Ayala GU, Camacho GJ, Sanchez AC. Enchondroma of the distal phalanx. *Acta Ortop Mex.* 2011; 25: 375–8.
- Murphey MD, Flemming DJ, Boyea SR, Bojescul JA, Sweet DE, Temple HT, et al. Enchondroma versus chondrosarcoma in the appendicular skeleton: Differentiating features. *Radiographics.* 1998; 18: 1213–37. PMID: 9747616. <https://doi.org/10.1148/radiographics.18.5.9747616>
- Marco RA, Gitelis S, Brebach GT, Healey JH. Cartilage tumors: Evaluation and treatment. *J Am Acad Orthop Surg.* 2000; 8: 292–304. PMID: 11029557. <https://doi.org/10.5435/00124635-200009000-00003>
- Jaffe HL, Lichtenstein L. Solitary unicameral bone cyst with emphasis on the roentgen picture, the pathologic appearance and the pathogenesis. *Arch Surg.* 1942; 44: 1004–25. <https://doi.org/10.1001/archsurg.1942.01210240043003>
- Cottalorda J, Bourelle S. Modern concepts of primary aneurismal bone cyst. *Arch Orthop Trauma Surg.* 2007; 127: 105–14. PMID: 16937137. <https://doi.org/10.1007/s00402-006-0223-5>
- Lichtenstein L. Aneurysmal bone cyst: A pathological entity commonly mistaken for giant cell tumor and occasionally for hemangioma and osteogenic sarcoma. *Cancer.* 1950; 3: 279–89. [https://doi.org/10.1002/1097-0142\(1950\)3:2<279::AID-CNCR2820030209>3.0.CO;2-F](https://doi.org/10.1002/1097-0142(1950)3:2<279::AID-CNCR2820030209>3.0.CO;2-F)
- Iltar S, Alemdaroglu KB, Karalezli N, Irgit K, Caydere M, Aydogan NH. A case of an aneurysmal bone cyst of a metatarsal: Review of the differential diagnosis and treatment options. *J Foot Ankle Surg.* 2009; 48: 74–9. PMID: 19110164. <https://doi.org/10.1053/j.jfas.2008.10.001>
- Singer Ad, et al. Benign and malignant tumors of the foot and ankle. *Skeletal Radiol.* 2016; 45: 287–305. PMID: 26530393. <https://doi.org/10.1007/s00256-015-2278-2>
- Schatz J, et al. Imaging of tumors in the ankle and foot. *Top Magn Reson Imaging.* 2010; 21: 37–50. PMID: 21317567. <https://doi.org/10.1097/RMR.0b013e31820ef556>
- Ruggieri P, Angelini A, Jorge FD, Maraldi M, Giannini S. Review of foot tumors seen in a university tumor institute. *J Foot Ankle Surg.* 2014; 53: 282–5. PMID: 24751209. <https://doi.org/10.1053/j.jfas.2014.01.015>
- Fayad LM, Ahlawat S, Khan MS. Chondrosarcomas of the hands and feet: A case series and systematic review of the literature. *Eur J Radiol.* 2015; 84: 2004–12. PMID: 26189572. <https://doi.org/10.1016/j.ejrad.2015.06.026>
- Ogose A, Unni KK, Swee RG, et al. Chondrosarcoma of small bones of the hands and feet. *Cancer* 1997; 80: 50–9. [https://doi.org/10.1002/\(SICI\)1097-0142\(19970701\)80:1<50::AID-CNCR7>3.0.CO;2-J](https://doi.org/10.1002/(SICI)1097-0142(19970701)80:1<50::AID-CNCR7>3.0.CO;2-J)
- Nielsen GP, O'Connell JX. Tumors of synovial tissue. Folpe AL, Inwards CY, editors. *Bone and soft tissue pathology*. Philadelphia: Saunders/Elsevier; 2010. p. 255–61. <https://doi.org/10.1016/B978-0-443-06688-7.00013-4>
- International Society for the Study of Vascular Anomalies. ISSVA classification of vascular anomalies. 2014. 2018 Jan 28. [issva.org/classification](http://issva.org/classification)

**How to cite this article:** Sharma PJ, Komatwar P, Takle AK. Magnetic Resonance Imaging Evaluation of Various Neoplastic Lesions of Ankle and Foot at a Tertiary Health Care Centre. *MVP J. Med. Sci.* 2022; 9(1): 37-45.