

Functional Outcome in Intertrochanteric Femur Fracture Fixation using Proximal Femur Nail

Deepak Kumar Singh¹, Rajesh Sonawane^{2*}, Sandeep Pangavane³, Nitin Wagh⁴, Satyen Joshi⁴, Pranit Sonawane⁵, Ashutosh Ushir², Ajit Jangle⁵ and Tanay Goyal¹

¹Former PG Resident, Department of Orthopedics, Dr. Vasant Rao Pawar Medical College, Hospital and Research Centre, Nashik – 422003, Maharashtra, India

²Assistant Professor, Department of Orthopedics, Dr. Vasant Rao Pawar Medical College, Hospital and Research Centre, Nashik – 422003, Maharashtra, India

³Professor and Head, Department of Orthopedics, Dr. Vasant Rao Pawar Medical College, Hospital and Research Centre, Nashik – 422003, Maharashtra, India

⁴Associate Professor, Department of Orthopedics, Dr. Vasant Rao Pawar Medical College, Hospital and Research Centre, Nashik – 422003, Maharashtra, India

⁵Senior Resident, Department of Orthopedics, Dr. Vasant Rao Pawar Medical College, Hospital and Research Centre, Nashik – 422003, Maharashtra, India

Abstract

Background: This study was conducted to assess the functional outcome of Proximal Femoral Nailing in fixation of Intertrochanteric fractures of Femur. **Methods:** After obtaining written consent, this prospective study was conducted among 127 patients (age group >18 years) who had inter-trochanteric fracture with or without subtrochanteric extension fixed using proximal femoral nail. Mobilisation was started between first week to 6th week of fracture fixation depending on the rigidity of fixation and pain tolerance of the patient. Patients were followed up at 6th week, 3rd month and 6th month after operative fixation. Functional outcome was assessed using a physician based scoring system i.e. Harris Hip Score at every follow up. Scores were tabulated and assessment was done. **Results:** The present study included, 54 females (42.5%) and 73 males (57.5%) in the age group of 28 years to 94 years with the mean age of 67.7 years. Unstable inter-trochanteric fractures were seen in 106 cases (83.5%) 'Fair' results were seen in 17 (13.4%), 'Good' results seen in 61 (48.0%), 'Excellent' results were seen in 37 (29.1%) patients at the end of 6 months follow up. Intraoperative complications were seen in 4 patients and late complications seen in 13 patients. **Conclusion:** From this study, we consider that PFN is an excellent implant for the treatment of intertrochanteric fractures. With a proper technique, PFN gives excellent clinical results with fewer failure rates and complications.

Keywords: Harris Hip Score, Intertrochanteric Fractures, Proximal Femur Nail

1. Introduction

Among the fractures encountered in clinical practice of an Orthopaedic Surgeon, intertrochanteric fractures are one of the commonest injuries sustained by the elderly population. The incidence of these fractures have gone up rapidly due to significant increase in life span of human population and lifestyle alterations^{1,2}. In the contemporary era, due to rapid industrialization and automobiles these

fracture types have also become common in younger age group³. In young and healthy individuals, these injuries result from high-velocity traumatic insults, whereas in the geriatric population, most of these fractures are osteoporotic and some pathological, mostly resulting from a trivial fall⁴.

The fundamental side-effects of prolonged immobilization include deep vein thrombosis, pulmonary thrombo-embolism, decubitus ulcers, urinary tract

*Author for correspondence

infections, joint contractures and aspiration pneumonia⁵ which lead to an enormous burden on the health care services^{6,7}. Since this fracture is predominant in older age population, the aim of treatment is early stabilization, rigid and stable fixation, in order to prevent the complications of prolonged recumbency. This has directed the need for surgery by internal fixation for these type of fractures.

The advantages of operative treatment are:

1. Decreases duration of hospitalization⁸
2. Reduces complications associated with prolonged immobilisation and recumbency⁸
3. Early mobilization and weight bearing is possible with early and adequate fracture fixation^{8,9}

There are several implants invented and described for fixation of Intertrochanteric fractures. The two of the most popular types of fixation methods used for intertrochanteric fractures with or without subtrochanteric extension are:

1. Extramedullary fixation with sliding hip screws with plate.
2. Intramedullary fixation with cephalomedullary nails.

Both Cephalo-Medullary Nails (CMN) and Sliding Hip Screws (SHS) are utilized as the standard of care for fixation of these fractures. Operative management with either fixation device allows for early rehabilitation and decreased morbidity and mortality¹⁰⁻¹². Biomechanical studies have shown that intramedullary device with sliding screw is better than sliding hip screw. As a result, intramedullary devices are emerging as the treatment of choice for these fractures^{13,14}.

In 1996, Arbeitsgemeinschaft für Osteosynthesefragen (AO/ASIF) developed the Proximal Femoral Nail (PFN) as an intramedullary device for the treatment of stable and unstable intertrochanteric and subtrochanteric femoral fractures. The fixation of fracture with PFN offers minimal surgical incision and thus reduces the risk of infection¹⁵.

The current study has been undertaken to evaluate and assess the functional outcome in cases where proximal femur nail, which is a relatively newer implant, is used for fixation of Intertrochanteric fractures.

2. Aims and Objectives

To study the functional outcome in patients with intertrochanteric fractures fixed using Proximal Femur Nail.

3. Material and Methods

This was a prospective study conducted at Department of Orthopedics, Dr. Vasanttrao Pawar Medical College, Hospital and Research Centre, Nashik, Maharashtra, India after being approved by the Institutional Ethics committee. Study duration was from August 2017 to December 2019.

127 patients were included and followed up for 6 months. All Patients, irrespective of gender, presenting to the emergency department with any of the four types of Intertrochanteric femur fractures as per Boyd and Griffin Criteria, above the age of 18 years who willfully consented to participate in the study were included in the study. All cases with open hip fractures, pathological fractures, peri prosthetic fractures, pediatric age group fractures (before physeal closure) and patients in whom surgical management was contraindicated were excluded from the study.

3.1 Methodology

3.1.1 Pre-Operative

After admission, necessary clinical and radiological evaluation was done.

The fractures were classified according to Boyd and Griffin classification of Intertrochanteric fractures. All patients were evaluated for associated medical/surgical problems and treated accordingly.

Patients were operated after taking fitness for surgery. Prophylactic antibiotic were given to all patients half an hour before surgery. All the patients were operated at an average interval of 7 days from the date of trauma.

3.1.2 Operative Technique

Under spinal or general anaesthesia, patients were operated in supine position on traction table with adduction (10°-15°) of the affected limb while the contralateral uninjured leg was placed on a leg holder in abduction. Closed reduction of the fracture was done by first giving traction in order to distract the fragments and regain length followed by internal rotation of the leg and it was checked under C-Arm in AP view by seeing the alignment of medial cortex and in lateral view the posterior cortex.

Under all aseptic conditions after proper painting and draping, A longitudinal incision of approximately 4-5 cm was given extending upwards from tip of greater

trochanter. Skin, subcutaneous tissue cut, deep fascia cut, the entry was made from tip of greater trochanter with the help of bone awl. A guide was inserted through this entry point into the femoral canal under C-Arm control, followed by sequential reaming of the femoral fragment. Then an assembled standard stainless steel PFN of appropriate size was inserted through the entry point and passed through fracture site. Then proximal locking was done with the help of jig and then distal locking was done under C-Arm control. Wound was washed with normal saline and betadine. Wound was sutured in layers. Aseptic dressing was done and crepe bandage applied.

3.1.3 Post-Operative Follow Up

Patients were kept in recovery room and vitals were monitored for 6-8 hours. Foot-end elevation was given overnight. Appropriate antibiotics (usually a 3rd generation cephalosporin) were given. Analgesics were given as per patient compliance with care to avoid excessive use of narcotics. Sutures were removed on 12th-14th postoperative day with aseptic precautions.

3.1.4 Mobilisation

Quadriceps strengthening exercises, ankle pumps and movements of hip and knee joints were started from post operative day 1 or as per subjective tolerance of pain. Early mobilization out of bed with non-weight bearing was started usually after first aseptic dressing change which was usually done on the 5th day and continued up to 4-6 weeks depending on the fracture pattern. Depending upon the rigidity of the fixation, partial weight bearing initiated after 4 days to 4 weeks. After confirmation of healing process done till fracture union on serial follow up. Full weight bearing was allowed after fracture union. Patients were advised to follow up at 6th week, 3rd month and 6th month after surgery. Functional outcome in patients was assessed at each follow up using the Harris Hip Score questionnaire.

3.1.5 Harris hip Score

Harris Hip Score is a physician-based assessment tool for post op patients that uses online calculation based questionnaire to give scores for relevant functional outcomes^{16,17} (Table 1).

It has three sections with four dimensions with score range from 0-100:

Sections 1:

a. Pain(Scored from 0-44)

b. Function(Scored from 0-47)

Section 2: Deformity (Scored from 0-4)

Section 3: Range of motion (Scored from 0-5)

Table 1. Grading for the harris hip score

Grade	Poor	Fair	Good	Excellent
Score	<70	70-79	80-89	90-100

4. Results

In our study of 127 adult patients, 83.4% of the patients were above the age of 50 years. In our study youngest patient had age of 28 years and oldest had an age of 94 years with a mean age of 67.7 years (Figure 1).

Figure 2 shows that most (58%) of the patients in our study were males and 42% were females, signifying a male preponderance in this study.

Figure 3 shows that majority of the patients (85.1%) sustained fractures due to trivial trauma like domestic fall and fall from stairs while rest of the patients sustained injury through road traffic accidents.

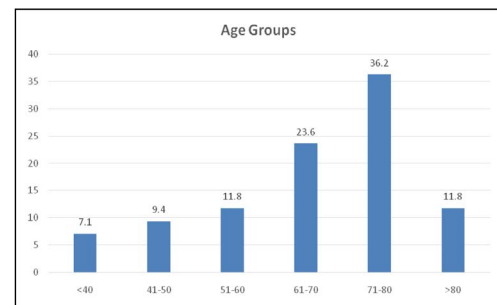


Figure 1. Age group of patients presenting with intertrochanteric femur fracture fixed with PFN.

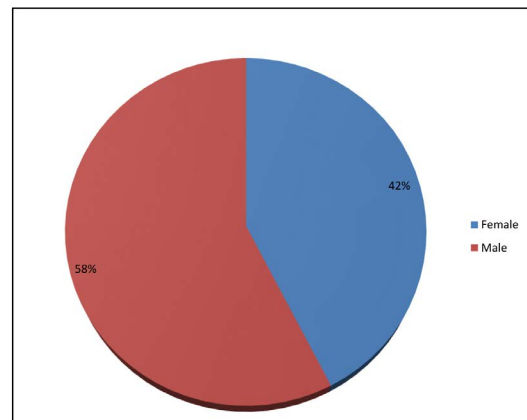


Figure 2. Gender distribution of study participants.

Figure 4 shows right side was affected in 51% of patients and left side was affected in 49% of patients.

In our study, we used Boyd and Griffin classification of intertrochanteric fractures, with majority were classified as type II (63%), making this the commonest type in our study followed by 16.5% type I then 11.8 % were type III and remaining 8.7% as type IV fractures (Figure 5).

Stable Intertrochanteric fractures have been defined as fractures with intact posteromedial cortex and little or no comminution. Accordingly Type I Boyd and Griffin Fractures are classified as stable fractures. In our study

16% fractures were stable. Unstable intertrochanteric femur fractures are the ones disrupted posteromedial cortex and comminution where reduction and fixation becomes difficult. In our study 84% fractures were classified as unstable IT fractures (Figure 6).

Functional Outcomes significantly improved from 1% in 'Good' or 'Excellent' category (i.e. Harris Hip Score >80) at 6 weeks to 77.1% at the end of 6 months. The difference between pre op and post op outcomes is statistically highly significant with p value <0.0001 (Table 2).

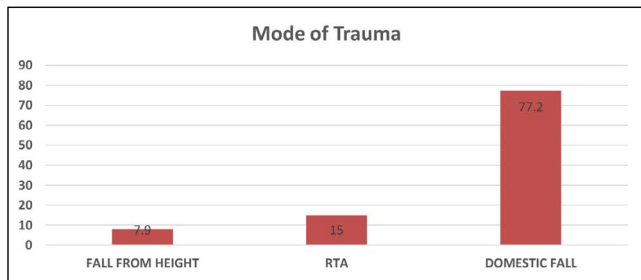


Figure 3. Mode of trauma.

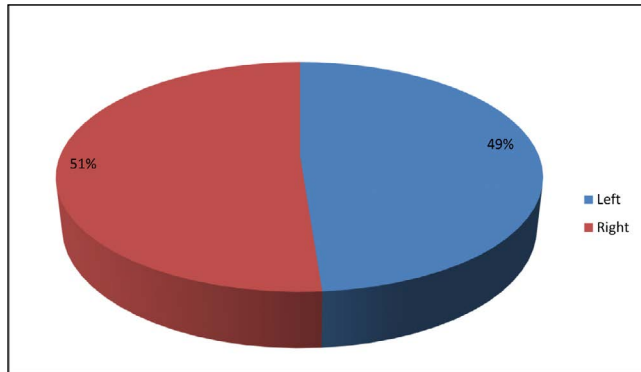


Figure 4. Side predisposition.

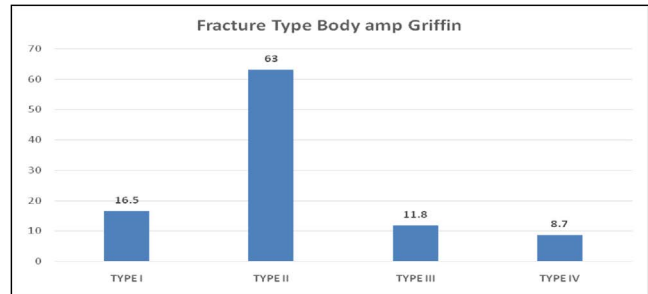


Figure 5. Chart showing the frequency of various types of fractures included in study.

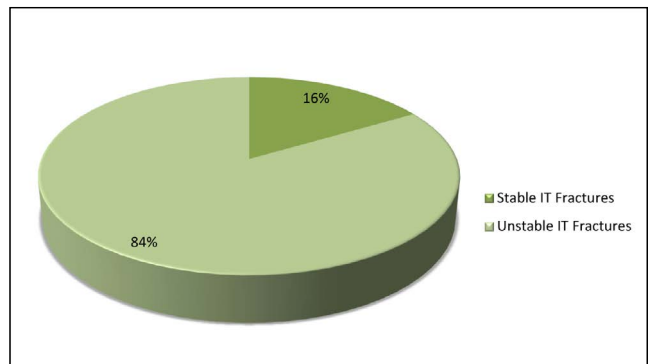


Figure 6. Stability pattern.

Table 2. Harris hip score at 6th week, 3rd month and 6th month follow up

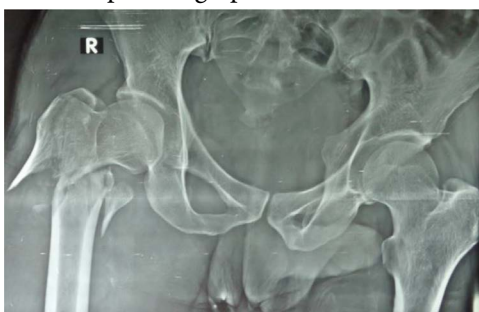Harris Hip Score Grade	Harris Hip Score at 6 weeks		Harris Hip Score at 3 months		Harris Hip Score at 6 months	
	Frequency	Percent	Frequency	Percent	Frequency	Percent
Poor	104	81.9	36	28.3	12	9.4
Fair	22	17.3	52	40.9	17	13.4
Good	1	.8	38	29.9	61	48.0
Excellent	0	0	1	.8	37	29.1
Total	127	100	127	100	127	100
Mean	60.858		73.129		81.956	
Standard Deviation	7.2128		10.2031		14.5051	
p-value	<0.0001		<0.0001		<0.0001	
Statistical Significance	Highly significant		Highly significant		Highly significant	

Out of 127 cases, we encountered two cases where the nail got jammed while insertion. There was one case each of lateral cortical walls of femur fracture and guide wire breakage noted during drilling for lag screw (Table 3).

In this study, as many as 13 cases had long term complications, 7 patients having more than one (Table 4).

4.1 Clinical Pictures

Picture 1: Pre Op Radiograph:



Picture 2: Immediate Post Op Radiograph:

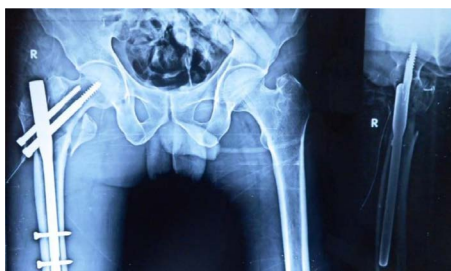

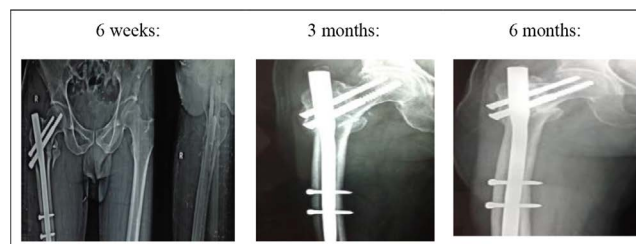Table 3. Intra operative complications

Intra-Op Complications	Frequency
Fracture of Lateral Cortex	1
Guide Wire Breakage	1
Jamming of Nail	2
Total	4


Table 4. Long term complications seen on follow up at the end of 6 months

Long Term Complications	Frequency
Delayed Union	1
Implant Failure	4
Infection	3
Shortening	3
Knee Stiffness	3
Varus Malreduction	2
Non Union	3
Total	19

Picture 3: Follow Up Radiographs:



Picture 4: Functional Outcome at 6 months:



5. Discussion

Operative treatment in the form of internal fixation permits early rehabilitation and offers the best chance of functional recovery and hence has become the treatment of choice for intertrochanteric femur fractures.

Since intertrochanteric fracture is most commonly seen in elderly patients, osteoporosis was taken into consideration. Osteoporosis is a condition characterized by low bone mineral density and compromised microarchitectural integrity leading to structural failure of skeleton even at low load. Singh's (2012)¹⁸ Grading of osteoporosis is used to evaluate the quality of bone. However for outcome surgery, the combined influence of osteoporosis and fracture pattern is considered along with quality of surgical fixation. This study shows that as the age advances outdoor fractures due to trivial trauma become more significant e.g simple domestic falls which is aided by osteoporosis in the bones of elderly.

Several types of compression hip-screws with a plate have been used for treatment of intertrochanteric fractures. They provide stable fixation and controlled impaction over the fracture. But their use in intertrochanteric fractures has not been satisfactory due to excessive sliding of lag screw and medialization of distal fragment and subsequent fixation failure¹⁹.

AO/ASIF in 1996 developed the PFN as an intramedullary device for the treatment of unstable and stable intertrochanteric femoral fractures. Proximal

femoral nail has all the advantages of an intramedullary device, such as decreasing the moment arm, can be inserted by closed technique, which retains the fracture hematoma an important consideration in fracture healing decreases blood loss, infection, minimizes the soft tissue dissection and wound complications¹⁵.

In the present study, we used proximal femoral nail for treatment of 127 cases of inter trochanteric fractures. Rohit and Roland *et al.*²⁰ studied 25 patients of trochanteric fracture in that 17 are male patients. Minos Tyllianakis *et al.* (2004)²¹ a retrospective study of the treatment of unstable intertrochanteric fractures of the proximal femur using proximal femoral nail in 45 patients. In that a fall at home was the commonest mode of injury (67% of the patients). Similarly in our study also slip and fall was the common mode of injury (77.2% patients). In his study the average time from injury to surgery was 3 days (range: 0 to 7 days) which was 7 days in our study. The mean operative time (skin to skin) in our study was 90 minutes compared to 68 minutes in his study.

Delayed union was seen in one patient who was identified at 6 month follow up xray. No active intervention was advised and patient was asked to follow up again after 3 months. 3 cases were identified as non union at 6 months and they will require bone grafting.

Two patients (1.36%) developed varus malunion with abductor lurch due to collapse of the medial cortex but fortunately the fracture was united and limb shortening of 1.0 cm occurred in this case. According to Werner-Tutschku *et al.* (2002)²² the incidence of varus consolidation is 11.2%.

Implant failure in the form of lag screw cut out was identified in 4 cases. They presented with lurch at successive follow ups and were unwilling for re-surgery. This was probably a result of early weight bearing in osteoporotic patients. Lei-Sheng Jiang *et al.* (2002)²³ in his study had no complications such as cutout or breakage of the implants, or periprosthetic fractures. He recommended that the lag screw of PFN should be placed in the lower part of the femoral neck close to the femoral calcar, with screw tip reaching the subchondral bone 5 to 10 mm below the articular cartilage in anteroposterior view. In lateral view, it should be placed in the centre of the femoral neck. There, the lag screw will be definitely placed in the area of best bone quality. Inger *et al.* (2002)²⁴ in his study on biomechanical evaluation of PFN also

concluded that if the hole through the nail of the hip pin was modified to a slot there is significant reduction of axial loads on hip pin thereby reducing the cut out risk²⁵.

Knee stiffness was identified as a complaint at 6th week follow up in 3 patients which improved dramatically on aggressive physiotherapy.

Werner *et al.* (2002)²⁶ was the first who introduced the term Z-effect, detected in 5 (7.1%) of 70 cases. 4 (3.14%) Patients had neck screw cut out and showed Z effect among the 127 patients.

The Z-effect phenomenon is referred as a characteristic sliding of the proximal screws to opposite directions during the postoperative weight-bearing period.

We did not find any cases of Z effect, Reverse Z effect or DVT in our study.

3 cases had shortening of 2cms, managed with shoe raise.

The average duration of surgery was 90 minutes. Blood loss-measured by mop count (each fully soaked mop containing 50ml blood) average was about 100ml. In our study the average duration of hospital stay was 12.5 days.

Four patients succumbed within one week of surgery. Two succumbed with Acute Respiratory Distress Syndrome, one with Pulmonary Fat Embolism and one with Acute Inferior Wall Myocardial Infarction. They were not included in the results of this study as follow up was not applicable. It is important to be watchful for signs of deterioration post operatively in these patients.

Inger *et al.* (2002)²⁴ using PFN and gamma nail in 413 patients found superficial infections was 25/413, deep infection in 11/413, hematoma in 17/413. In our study we had 3 patients of deep infection out of that one patient had deep infection on 4th post operative day and it was healed on 22nd post operative day. It was managed with wound debridement, parenteral antibiotics, and regular dressings.

Ekstr Am *et al.* (2007)²⁷ studied 203 patient with PFN and med off sliding plate he found that varus union was about 4.7% in PFN and 1.02% med off sliding plate in our study we had 2 cases with varus deformity probably due to non anatomical reduction and early weight bearing.

Overall, at the end of 6 months, we had well to excellent results in 77.1% of cases, Fair results in 17% and Poor result in 12% of cases.

6. Conclusion

From our study we conclude that intertrochanteric femur fracture fixation using PFN has satisfactory functional outcome with fewer complication rates at the ends of 6 months. Majority of the patients have good to Excellent Functional outcome after surgery.

7. References

1. Kannus P, Parkkari J, Sievänen H et al. Epidemiology of hip fractures. *Journal of Bone and Joints*, 1996; 18(1):57-63. [https://doi.org/10.1016/8756-3282\(95\)00381-9](https://doi.org/10.1016/8756-3282(95)00381-9).
2. Terry Canale S, James H Beaty. *Campbell's Operative orthopaedics*, Elsevier, 12th Edition.
3. Robert W Bucholz, James D Flückrnan, Charles M Court-Brown, Rockwood and Green's. *Fractures in Adults*, Vol 2, 6th Edition; p. 1827-1844.
4. Cooper A. *Fractures and Dislocations of the joints*. 10th edition London; 1839.
5. Muminagic SN. History of bone fracture: Treatment and immobilization. *Materia Socio-Medica*, 2011; 23(2):111. <https://doi.org/10.5455/msm.2011.23.111-116>.
6. Heyse M. Treatment of intertrochanteric fractures of femur. *JBJS*, 1983; 65-B:262-267. <https://doi.org/10.1302/0301-620X.65B3.6841393>. PMID:6841393.
7. Kaufer H, Mathews LS, Sonstegard D. Stable fixation of intertrochanteric fractures. *J Bone Joint Surg*, 1974; 56A:899-907. <https://doi.org/10.2106/00004623-197456050-00002>.
8. Robert Bucholez W, James Hechman D, Charles Court Brown M. *Rockwood Greens Fracture in Adults*, Vol 2, 6th Edition, Lippincott Williams and Wilkins Co; 2006. p. 1827-1844.
9. Novack V, Jotkowitz A, Etzion O, Porath A. Does delay in surgery after hip fracture lead to worse outcomes? A multicenter survey. *Int J Qual Health Care*, 2007; 19(3):170-176. <https://doi.org/10.1093/intqhc/mzm003>. PMID:17309897.
10. Rogers FB, Shackford SR, Keller MS. Early fixation reduces morbidity and mortality in elderly patients with hip fractures from low-impact falls. *J Trauma*, 1995; 39(2):261-265. <https://doi.org/10.1097/00005373-199508000-00012>. PMID:7674394.
11. Zuckerman JD, Skovron ML, Koval KJ, Aharonoff G, Frankel VH. Postoperative complications and mortality associated with operative delay in older patients who have a fracture of the hip. *J Bone Joint Surg Am*, 1995; 77(10):1551-1556. <https://doi.org/10.2106/00004623-199510000-00010>. PMID:7593064.
12. Curtis MJ, Jinnah RH, Wilson V, Cunningham BW. Proximal femoral fractures: A biomechanical study to compare intramedullary and extramedullary fixation. *Injury*, 1994; 25(2):99-104. [https://doi.org/10.1016/0020-1383\(94\)90111-2](https://doi.org/10.1016/0020-1383(94)90111-2).
13. Haynes RC, Poll RG, Miles AW, Weston RB. An experimental study of the failure modes of the Gamma Locking Nail and AO Dynamic Hip Screw under static loading: A cadaveric study. *Med Eng Phys*, 1997; 19:446-453. [https://doi.org/10.1016/S1350-4533\(97\)00003-9](https://doi.org/10.1016/S1350-4533(97)00003-9).
14. Kaufer H, Matthews LS, Sonstegard D. Stable Fixation of Intertrochanteric Fractures. *Journal of Bone and Joint Surgery*, 1974; 56A:899-907. <https://doi.org/10.2106/00004623-197456050-00002>.
15. Gulberg B, Duppe H, Nilsson B. Incidence of Hip Fractures in Malmo, Sweden. *Bone*, 1950-1991; 14(Suppl 1):23-29. [https://doi.org/10.1016/8756-3282\(93\)90345-B](https://doi.org/10.1016/8756-3282(93)90345-B).
16. Harris WH. Traumatic arthritis of the hip after dislocation and acetabular fractures: Treatment by moldarthroplasty. An end result study using a new method of result evaluation. *J Bone Joint Surg Am*, 1969 Jun; 51(4):737-55.
17. Marchetti P, Binazzi R, Vaccari V, Girolami M, Morici F, Impallomeni C, Commessatti M, Silvello L. Long-term results with cementless Fitek (or Fitmore) cups. *J Arthroplasty*, 2005 Sep; 20(6):730-723. <https://doi.org/10.1016/j.arth.2004.11.019>. PMID:16139709.
18. Singh RN, Singh BN, Kumar R. Comparative prospective study of proximal femoral nail and dynamic hip screw in treatment of intertrochanteric fracture femur. *Journal of Clinical Orthopaedics and Trauma*, 2012; 3(1):28-36. <https://doi.org/10.1016/j.jcot.2011.12.001>. PMID:25983453 PMID:PMC3876488.
19. Dominique Hardy CR, Pierre-Yves Descamps, Panagiotis Krallis et al. Use of intramedullary hip screw compared with a compression hip screw with a plate for intertrochanteric femoral fractures. A prospective, randomized study of one hundred patients. *JBJS*, 1998; 80-A:5. <https://doi.org/10.2106/00004623-199805000-00002>. PMID:9611022.
20. Rohit, Roland et al. *International Journal of Health and Sciences*. 3(1):417-425.
21. Tyllianakis M, Panagopoulos A, Papadopoulos A, Papisimos S, Mousafiris K. Treatment of extracapsular hip fractures with the Proximal Femoral Nail (PFN): Long term results in 45 patients. *Acta Orthop Belg*, 2004; 70(5):444-454.
22. Werner-Tutschku W, Lajtai G, Schmiedhuber G, Lang T, Pirkl C, Orthner E. Intra- and perioperative complications in the stabilization of per- and subtrochanteric femoral fractures by means of PFN. *Unfallchirurg*, 2002; 105(10):881-885. <https://doi.org/10.1007/s00113-002-0416-5>. PMID:12376894.
23. Lei-Sheng Jiang; Lei Shen; Li-Yang Dai. Intra medullary Fixation of subtrochanteric fractures with Long proximal

- femoral nail or Long Gamma Nail. Technical Notes and Preliminary Results. *Ann Acad Med Singapore*, 2007; 36; 821-826.
24. Inger B Schipper, Stephen Bresina, Dieter Wahl et al. Bio mechanical evaluation of the Proximal Femoral nail. *Clinical Orthopaedics and Related Research*. Lipincott, Williams and wilkins Inc; 2002. No 405, p. 277-286. <https://doi.org/10.1097/00003086-200212000-00035>. PMID:12461384.
 25. Christian Boldin. The proximal femoral nail-a minimal invasive treatment of unstable proximal femoral fractures. *Acta Orthop Scand*, 2003; 74(1):53-58. <https://doi.org/10.1080/00016470310013662>. PMID:12635794.
 26. Werner-Tutschku W, Lajtai G, Schmiedhuber G, Lang T, Pirkel C, Orthner E. Intra- and perioperative complications in the stabilization of per- and subtrochanteric femoral fractures by means of PFN. *Unfallchirurg*, 2002; 105(10):881-885. <https://doi.org/10.1007/s00113-002-0416-5>. PMID:12376894.
 27. Ekstram W, Karlsson-Thur C, Larsson S Et Al. Functional outcome in treatment of unstable trochanteric and subtrochanteric fractures with the proximal femoral nail and the med off sliding plate. *J Orthop Trauma*, 2007; 21(21):18-25. <https://doi.org/10.1097/BOT.0b013e31802b41cf>. PMID:17211264.

How to cite this article: Singh, D.K., Sonawane, R., Pangavane, S., Wagh, N., Joshi, S., Sonawane, P., Ushir, A., Jangle, A. and Goyal, T. Functional Outcome in Intertrochanteric Femur Fracture Fixation using Proximal Femur Nail. *MVP J. Med. Sci.* 2021; 8(1): 78-85.