

# Tinea Incognito due to Over the Counter Drug Application: A Case Report

Shwetal Rathi<sup>1\*</sup>, Vijay Zavar<sup>2</sup>, Rahul Kote<sup>3</sup> and Vivek Nikam<sup>4</sup>

<sup>1</sup>Former PG Resident, Department of Dermatology, Dr. Vasant Rao Pawar Medical College Hospital and Research Centre, Nashik – 422203, Maharashtra, India; radharathi0912@gmail.com

<sup>2</sup>Professor and Head, Department of Dermatology, Dr. Vasant Rao Pawar Medical College Hospital and Research Centre, Nashik – 422203, Maharashtra, India

<sup>3</sup>Associate Professor, Department of Dermatology, Dr. Vasant Rao Pawar Medical College Hospital and Research Centre, Nashik – 422203, Maharashtra, India

<sup>4</sup>Assistant Professor, Department of Dermatology, Dr. Vasant Rao Pawar Medical College Hospital and Research Centre, Nashik – 422203, Maharashtra, India

## Abstract

Tinea incognito caused by of over the counter and overuse of topical steroids resulting in various clinical presentations making it difficult to diagnose. Now-a-days over the counter use of topical combinations containing steroids have increased. We present here a case of an adult female presented with lichenified plaque over both buttocks, abdomen and lower limbs associated with itching with history of over the counter application of topical steroid containing combination on her own. KOH mount of skin scraping confirmed the diagnosis. Treatment with systemic and topical antifungals for 6 weeks resulted into remarkable improvement.

**Keywords:** Over the Counter Drugs, Steroids, Tinea Incognito, KOH Mount

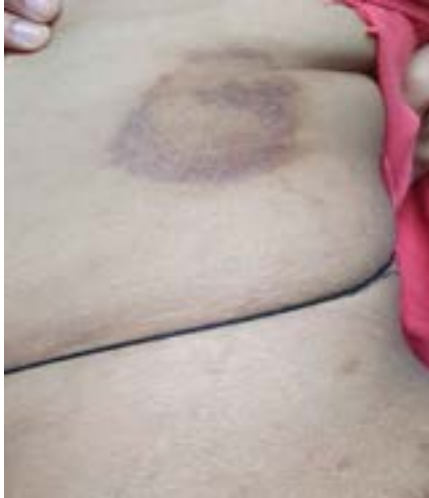## 1. Introduction

In 1968, the term-tinea incognito was used by Ive and Marks for patients with clinical features mimicking seborrheic dermatitis, lichen ruber planus, folliculitis, scleroderma and rosacea due to overuse of steroids on initial dermatophytic lesions<sup>1</sup>. Tinea incognito is a variant of superficial fungal infection in which the clinical presentation of patient is modified by over use of topical corticosteroid which was used either mistakenly for misdiagnosed tinea or applied over the counter. The patient usually improves with the application of topical steroids in initial days leading to over the counter use of it on their own. All this leads to frequent relapse and slow improvement with antifungal drugs<sup>2</sup>. Its atypical presentation can easily lead to improper diagnosis and delayed treatment<sup>3</sup>.

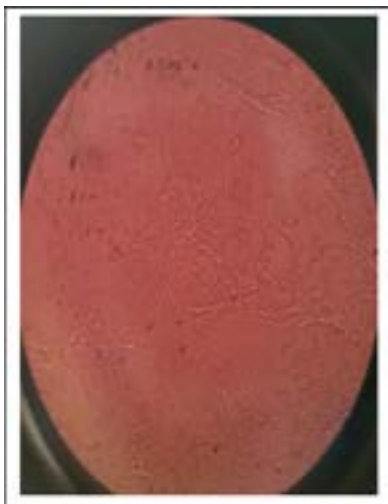
## 2. Case Report

A 22 year female patient came with complaint of red to dark colored elevated lesions over the abdomen, buttocks and lower limbs associated with itching more in night since 4 months. Initially the lesions were annular and patient was applying topical cream which consist of clobetasol propionate 0.05%, terbinafine 1%, ofloxacin 0.75% and ornidazole 2% on her own since 4 months. There is no history of any watery discharge, pain. Family history of similar complaints were present in the family members. Patient denied of similar complaints in past. She was not a known case of DM/HTN. On examination, multiple well-defined hyperpigmented lichenified plaques of variable sizes with little scaling were present over both buttocks, lower limbs. Annular plaque with multiple erythematous papules at one end was present over left side

\*Author for correspondence



**Figure 1.** Well defined annular erythematous plaque with popular borders.



**Figure 2.** Branched septate fungal hyphae seen on KOH mount.

of abdomen (Figure 1). On the basis of clinical history and examination, we suspected that patient might have tinea infection since 4 months but on examination there was no central clearing and scaling at periphery. Clinical picture was more in favor of eczema. To confirm the diagnosis, KOH mount was prepared and seen at 40X under microscope which showed multiple septate branching hyphae confirming fungal infection as etiology (Figure

2). Patient was treated with Capsule Itraconazole 100mg twice daily for 6 weeks along with topical sertaconazole 1% lotion twice daily and tab levocitrizine 10 mg at night. Family members were also encouraged to take treatment. Remarkable improvement was seen in patient at end of 6 weeks.

### 3. Discussion

Tinea incognito acts as a great imitator with clinical features mimicking eczema, atopic eczema, discoid lupus erythematosus, psoriasis, chronic hand eczema, pyoderma, Seborrheic dermatitis, scleroderma, erythema migrans, etc<sup>2-4</sup>. Steroids subvert the Th1/Th2 response, affect the antigen receptor recognition capacity of Langerhans' cells and reduced production of inflammatory markers like interleukin-1 (both IL-1 $\alpha$  and IL-1 $\beta$ ), interferon- $\gamma$ , tumor necrosis alpha and many others<sup>5</sup>. Hence, health education of community discouraging OTC use of topical steroids and other combinations is pivotal. Knowledge of deviated clinical presentations is extremely important to avoid misdiagnosis and initiate appropriate treatment.

### 4. References

1. Ive FA, Marks R. Tinea incognito. *Br Med J*. 1968; 3: 149-52. <https://doi.org/10.1136/bmj.3.5611.149> PMID:5662546 PMCID:PMC1986136
2. Dhaher S. Tinea incognito: Clinical perspectives of a new imitator. *Dermatology Reports*. 2020 Jun 25; 12(1). <https://doi.org/10.4081/dr.2020.8323> PMID:32655844 PMCID:PMC7341072
3. Feder HM. Tinea incognito misdiagnosed as erythema migrans. *New Engl J Med*. 2000; 343:69. <https://doi.org/10.1056/NEJM200007063430116> PMID:10896550
4. Romano C, Maritati E, Gianni C. Tinea incognito in Italy: A 15-year survey. *Mycoses*. 2006 Sep; 49(5):383-7. <https://doi.org/10.1111/j.1439-0507.2006.01251.x> PMID:16922789
5. Sardana K, Kaur R, Arora P, Goyal R, Ghunawat S. Is antifungal resistance a cause for treatment failure in dermatophytosis: A study focused on tinea corporis and cruris from a tertiary centre? *Indian Dermatology Online Journal*. 2018 Mar; 9(2):90. [https://doi.org/10.4103/idoj.IDOJ\\_137\\_17](https://doi.org/10.4103/idoj.IDOJ_137_17) PMID:29644192 PMCID:PMC5885633

**How to cite this article:** Rathi, S., Zavar, V., Kote R. and Nikam, V. Tinea Incognito due to Over the Counter Drug Application: A Case Report. *MVP J. Med. Sci.* 2020; 8(2): 321-322.