

# Unstable Intertrochanteric Femur Fracture in Elderly Treated with Bipolar Hemiarthroplasty Versus Dynamic Hip Screw - A Prospective Comparative Study

Sandeep Pangavane<sup>1</sup>, Nikhil Challawar<sup>2</sup>, Ameya Kulkarni<sup>3\*</sup>, Nimesh Nebhani<sup>3</sup>, Nitish Agrawal<sup>3</sup> and Bhalchandra Bhalerao<sup>3</sup>

<sup>1</sup>Professor and HOD, Department of Orthopedics, Dr. Vasant Rao Pawar Medical College, Hospital and Research Centre, Nashik – 422003, Maharashtra, India; drpangavane@gmail.com

<sup>2</sup>Assistant Professor, Department of Orthopedics, Dr. Vasant Rao Pawar Medical College, Hospital and Research Centre, Nashik – 422003, Maharashtra, India; drnikhilortho@gmail.com

<sup>3</sup>Post-Graduate Resident, Department of Orthopedics, Dr. Vasant Rao Pawar Medical College, Hospital and Research Centre, Nashik – 422003, Maharashtra, India; theauk9@gmail.com, nimcy805@gmail.com, nitishagrawal1234@gmail.com, bhalchandrabhalerao@gmail.com

## Abstract

**Introduction:** Intertrochanteric fractures are one of the most common fractures in elderly population and have a huge impact on the health care system of the society. **Objectives:** The objective of our study was to compare functional outcome and complication rates of bipolar hemiarthroplasty to dynamic hip screw which is a established procedure for unstable intertrochanteric fracture femur. **Materials and Methods:** The present study included 50 patients over the age of 55 years, 25 undergoing bipolar hemiarthroplasty and 25 undergoing dynamic hip screw for unstable intertrochanteric fracture femur and their functional outcomes were compared with Harris hip score. **Results:** We found that the average Harris hip score was better for the bipolar hemiarthroplasty group than for the dynamic hip screw group at 6 months. **Conclusion:** Bipolar hemiarthroplasty is an effective alternative to dynamic hip screw for unstable intertrochanteric fractures in elderly patients as it has a good function outcome and lower complication rate. A larger randomized control trial has to be conducted to arrive at a conclusion.

**Keywords:** Dynamic Hip Screw, Primary Bipolar Hemiarthroplasty, Unstable Inter-trochanteric Fractures

## 1. Introduction

Proximal femoral fractures in elderly individuals have a tremendous impact on both the health care system and society and it occurs in moderate or minimal trauma<sup>1,2</sup>. During an impact the large amount of energy that is released is absorbed by the skin, fat, and muscles which surround the hip. There is an increased incidence of hip fractures with aging due to decrease in muscle mass around the hip<sup>2</sup> and osteoporosis and is becoming more common as the proportion of elderly people in the population increases<sup>3</sup>.

The treatment of trochanteric hip fractures with internal fixation has improved drastically in the last few decades. Still failure of internal fixation is a known complication<sup>4</sup>.

The failure after internal fixation had been due to initial fracture pattern, Comminutions, sub optimal fracture fixation and poor bone quality<sup>5</sup>. The problems associated with fixation of these fractures are loss of fixation, varus collapse and cut out of the lag screw<sup>6</sup>. As a result, there is profound functional disability and pain<sup>7</sup>. In these patients treatment with primary bipolar hemiarthroplasty decreases the post operative complications due to prolonged immobilization or implants failure and also quickly returns the patients to their pre-injury activity level<sup>6</sup>.

The purpose of our study was to evaluate the functional outcomes of primary bipolar hemiarthroplasty vs dynamic hip screw fixation for unstable intertrochanteric femur fractures in elderly patients.

## 2. Materials and Methods

This study was conducted at a tertiary health care center (unicentric) from August 2015 to December 2017 on 50 elderly (55 years and above) patients with unstable inter-trochanteric fractures who were divided in to two groups with  
 Group A – bipolar hemiarthroplasty (25 cases), and  
 Group B – dynamic hip screw (25 cases).

### 2.1 Inclusion Criteria

1. Age of patient 55 years and above.
2. Inter-trochanteric femur fracture confirmed on antero-posterior and lateral radiographs.
3. Unstable fractures (AO, A 2.1, A 2.2, A 2.3, and A 3.3 and Evans unstable fractures).
4. Patient ambulatory before fracture though may be using a cane or walker.
5. No other injuries.

### 2.2 Exclusion Criteria

1. Age less than 55 years.
2. Associated major injuries of lower extremity.
3. Any infection around the affected hip (soft tissue or bone).
4. Stable fracture.

### 2.3 Statistical Analysis

Data was reported as mean and significant difference between the two group's data was studied using Two-sample Wilcoxon rank-sum (Mann-Whitney) test.

### 2.4 Surgical Approach

**Group A:** Cemented bipolar hemiarthroplasty with calcar reconstruction and tension band wiring for greater trochanter.

*Posterior Moore's Approach*

**Group B:** Dynamic hip screw on traction table by Lateral approach.

**Randomization** (simple random technique): As the patients who got admitted in our hospital and fulfilled the inclusion criteria irrespective of other confounding factors; the serially presenting odd numbers were put in bipolar hemiarthroplasty group (group A) and the serially presenting even numbers to present were put in dynamic hip screw group (group B).

## 3. Results

Patients were evaluated clinically using Harris hip score during their follow up period. Based on the Harris Hip Score (HHS)<sup>8</sup>, the results were graded as (Table 1):

- Excellent: ≥90 points
- Good : 80–89 points
- Fair : 70–79 points
- Poor : <70 points

**Table 1.** HHS at follow up

| Follow up (Months) | Harris hip score | Harris hip score | P value |
|--------------------|------------------|------------------|---------|
|                    | Group A          | Group B          |         |
| 1 Months           | 70.90            | 62.09            | 0.00001 |
| 2 Months           | 76.73            | 67.05            | 0.00001 |
| 3 Months           | 83.40            | 73.71            | 0.002   |
| 6 Months           | 89.66            | 77.66            | 0.046   |

There was female preponderance in both groups (57%) in group A when compared to male (52%) in group B. Right side was more commonly involved in both group A (52%) and group B (56%). Fracture incidence was more common in age group of 60–69 years with group A (44%) and group B (56%). The mean age for group A and group B was 71.28 years and 70.09 respectively.

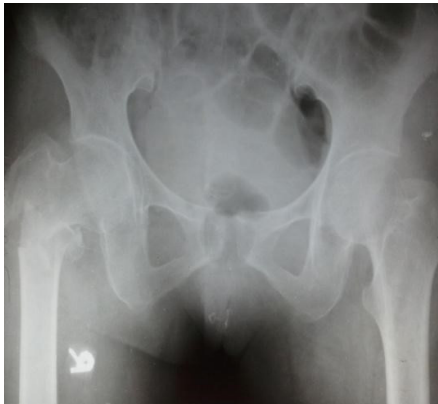Among the fracture distribution in AO classification type A 2.2 was more common in both group A (60%) and group B (56%). In Evans classification type IV was more common in both group A (56%) and group B (64%).

The commonest mode of injury in both the groups was accidental fall and other injuries accounting to 57.14% in Group A and 52.38% in Group B. In both groups the most common Singh's index was grade III, 72% in both Group A and Group B. The mean operative time (minutes) was greater in group B (133.66) than in group A (116). P value 0.0004. The mean blood loss intraoperatively (ml) was higher in group B (167.52) than in group A (153.57). P value 0.0310. The mean blood transfusions (number of units) during hospital stay was greater in group B (1.3) than in group A (1.1). P value 0.0276. The mean follows up (months) for group A and group B is 11 & 10.7 respectively.

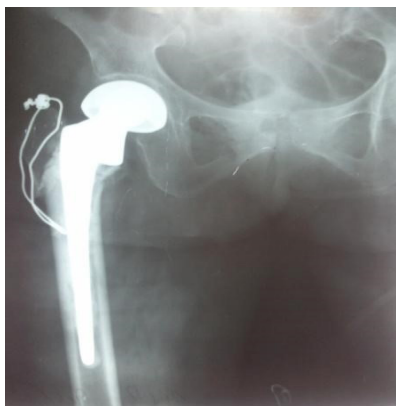Among postoperative complications, pressure sores, pulmonary complications and implant failure were in group B (4.7%) when compared to group A (0%). No difference was noted in both the groups in occurrence urinary tract infection. Infection was common in Group B (14.2%) as compared to group A (9.5%).

In group A, 3 patients had limb length discrepancy, 2 of them had shortening and one had lengthening. One patient was unable to ambulate due to associated medical problems.

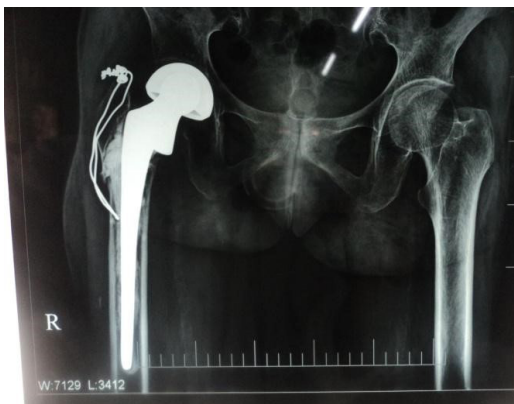
In group B, 2 patients had shortening, one patient had lag screw cutting out from femoral head, and 1 patient had marked pain during walking (Figure 1–6).



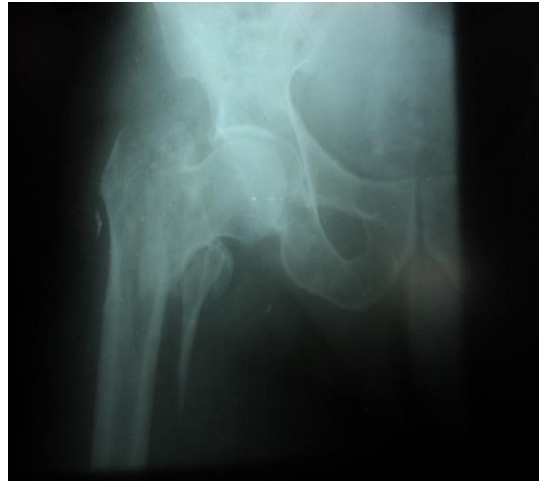**Figure 1.** Pre operative X ray.



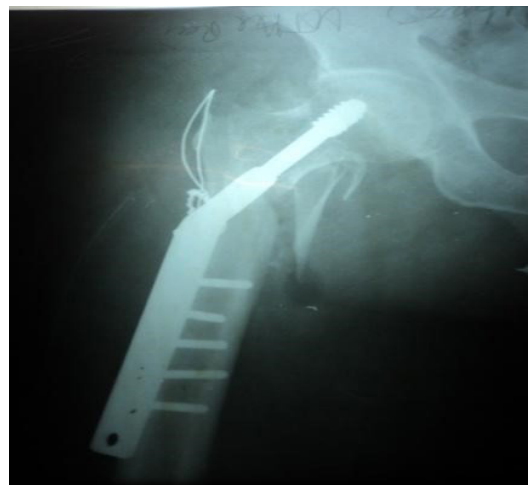**Figure 2.** Post operative X ray.



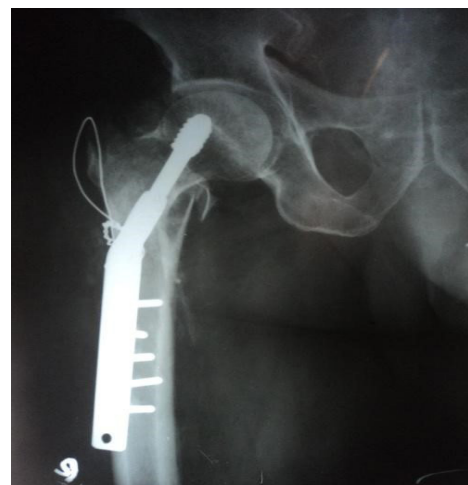
**Figure 3.** 6 month follow up.



**Figure 4.** Pre operative X ray.



**Figure 5.** Post operative X ray.



**Figure 6.** 6 months follow up.

## 4. Discussion

Intertrochanteric fractures are one of the most common fractures among elderly population. Although treatment for this has evolved in the past decades the morbidity post internal fixation is high and affects the productivity of the society. The treatment of unstable intertrochanteric fractures is still a dilemma due to nature of the fracture and difficulty in achieving stable internal fixation (Table 2).

**Table 2.** Type of Fracture

| Classification | AO    |       |       | Total | Evans |    | Total |
|----------------|-------|-------|-------|-------|-------|----|-------|
|                | A 2.1 | A 2.2 | A 2.3 |       | IV    | V  |       |
| Group A        | —     | 15    | 10    | 25    | 14    | 11 | 25    |
| Group B        | 05    | 14    | 06    | 25    | 16    | 09 | 25    |

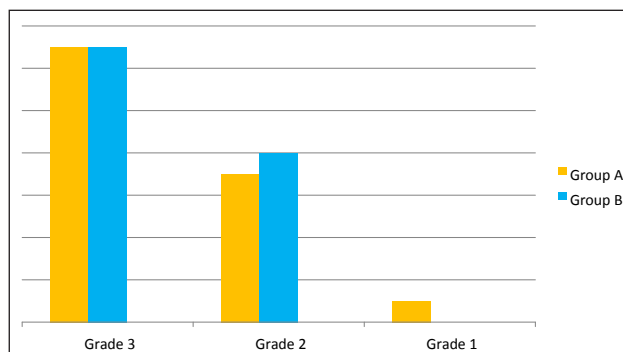
In group A, according to AO classification type A 2.2 was more common in 15 patients 60% and type A 2.3 in 40% patients. In Evans classification type IV was more common in 14 patients (56%) and type V in 11 patients (44%).

In group B, according to AO classification type A 2.2 was more common in 14 patients (56%), type A 2.3 in 6 patients (24%) and the A2.1 in 5 patients (20%). In Evans classification type IV was more common in 16 patients (64%) and type V in 9 patients (36%). Bipolar hemiarthroplasty has traditionally been done for intra-capsular neck femur fractures. Bipolar hemiarthroplasty has recently been used for treating unstable intertrochanteric femur fractures with good results. Bipolar hemiarthroplasty provides adequate stability and early rehabilitation according to some surgeons. Our aim was validate this hypothesis. The Intertrochanteric fractures are associated with a high mortality and morbidity in elderly patients. The overall one year mortality for hip fractures is 14%<sup>9</sup>. The mortality increases to up to 20% for at least 6-8 months to 1 year following a hip fracture compared to normal population<sup>10</sup>. Internal fixation in these patients reduced the mortality associated with these fractures<sup>11</sup> however failure rate is 56%<sup>12,13</sup> and early mobilization is avoided in case of osteoporosis, poor screw fixation and comminution.

The highly osteoporotic bone causes poor screw hold and leads to early biomechanical failure<sup>1-16</sup>.

### 4.1 Osteoporosis Evaluation

Singh's index in both the groups, grade 3 was more common in 18 patients. 6 patients had grade 2 in group A and 7 patients in group B. Grade 1 osteoporosis was seen in 1 patient in group A (Graph 1).



**Graph 1.** Grades of osteoporosis.

As a results femoral head collapses and migrates in to varus and retroversion<sup>17</sup>. This causes abductor liver arm shortening leading to abductor weakness and a limp<sup>18-21</sup>. Another cause for functional disability and pain in these patients is cutting out of the screw from the femoral head. Chances of screw cut-out are increased when there is inappropriate fracture reduction; superior screw position and a tip apex distance of more than 25mm<sup>22</sup>. The best lag screw position is a Centro central position<sup>23</sup>. Although the mortality rate is somewhat decreased with internal fixation, the complication rate still ranges from 4 to 50 percent elderly people with osteoporosis and unstable intertrochanteric fractures, internal fixation with Dynamic Hip Screw does not allow for unrestricted weight bearing<sup>24</sup>. It is important to achieve cortical alignment to achieve stability and avoid complication<sup>25</sup>.

Primary hemiarthroplasty in these patients provides adequate stability and early mobilization and early weight bearing<sup>26</sup>, alleviates pain and improves function. It also prevents post operative complications such as pneumonia, atelectasis and pressure sores and brings patient to pre injury level quicker<sup>27</sup>.

The results in group A were better than group B with respect to blood loss, operative time, perioperative blood transfusion this compares favourably with Sinno *et al.*<sup>28</sup> where one hundred and two patients participated in the study. Bipolar hemiarthroplasty was done in 48 patients and 54 patients were treated with dynamic hip screw fixation.

The mean operative time is less in group A (116 minutes) than that in group B, with a p value of 0.0004, which coincides with study by Sinno *et al.*<sup>28</sup> where it is 112 minutes and p value of 0.0001 in hemiarthroplasty group.

The amount of blood loss (mean) is lower in group A (153.5 ml )than in group B (167.5) with p value of 0.03, which is similar to the study by Sinno *et al.*<sup>28</sup> where it is 192 ml in hemiarthroplasty group with p value of 0.005.

The mean blood transfusions (units) is higher in group B (1.3) than in group A (1.1) with p value of 0.02, similar to that study where the mean blood transfusions was greater in internal fixation group (1.9) than in hemiarthroplasty group (1.37), with p value of 0.01

Early mobilization with full weight bearing in group A compared to non weight bearing or partial in group B shows reduction in pulmonary complications (4.7%) and pressure sores (4.7 %).

There was one case of deep infection and one superficial infection in group A, which comes around 9.5%, whereas in group B 3 patients had infection (14.2%), one of which is deep, which is higher than Sinno *et al.*<sup>28</sup> where they had 0% infection in hemiarthroplasty group and 4% in internal fixation group.

There were no cases of dislocation reported in our study. Two patients (9.5%) had shortening postoperatively with 1.5 cm and 2 cm. One patient had lengthening this was probably due to length of the auto graft used in reconstructing the calcar.

The Harris hip score was better in group A than in group B. The Harris hip score at 20 months follow up is significant with p value of 0.04 and were regarded as good in hemiarthroplasty group and fair in internal fixation group, which goes favourably with study by Sino K *et al.*<sup>28</sup> where at 24 months follow up the score was significant in hemiarthroplasty group with p value of 0.0001.

## 5. Conclusion

From our results, we are of the opinion that bipolar hemiarthroplasty may be an efficient option in elderly osteoporotic unstable intertrochanteric fractures. It reduces the potential complications of prolonged immobilization such as pressure sores, pulmonary complications etc by early mobilization. As there is improved function and decreased hospitalization it seems to be cost effective.

Though the results are encouraging in short term, a larger randomized prospective study comparing internal fixation and hemiarthroplasty is needed to arrive at a conclusion.

## 6. References

- Canale & Beaty: Campbell's Operative Orthopaedics, 11<sup>th</sup> ed.
- Rockwood & Green's Fractures in Adults, 6<sup>th</sup> Edition.
- Bartucci EJ, Gonzalez MH, Cooperman DR. The effect of adjunctive methylmethacrylate on failures of fixation and function in patients with intertrochanteric fractures and osteoporosis. *J. Bone Joint Surg. Am.* 1985; 67:1094-107. <https://doi.org/10.2106/00004623-198567070-00014>. PMID: 4030829.
- Audige L, Hanson B, Swiontkowski MF. Implant-related complications in the treatment of unstable intertrochanteric fractures: Meta-analysis of dynamic screwplate versus dynamic screw-intramedullary nail devices. *Int. Orthop.* 2003; 27: 197-203. <https://doi.org/10.1007/s00264-003-0457-6>. PMID: 12734684, PMCID: PMC3458474.
- Im GI, Shin YW, Song YJ. Potentially unstable intertrochanteric fractures. *J. Orthop. Trauma.* 2005; 19:5-9.
- Rodop O, Kiral A, Kaplan H, Akmaz I. Primary bipolar hemiprosthesis for unstable intertrochanteric fractures. *Int. Orthop.* 2002; 26:233-37. <https://doi.org/10.1007/s00264-002-0358-0>. PMID: 12185526, PMCID: PMC3620945.
- Hernigou P, Poignard A, Mathieu G, Cohen G, Manicom O, Filippini P. Total hip arthroplasty after failure of per- and subtrochanteric fracture fixation in elderly subjects. (French). *Rev. Chir. Orthop.* 2006;92. [https://doi.org/10.1016/S0035-1040\(06\)75760-9](https://doi.org/10.1016/S0035-1040(06)75760-9).
- Mahomed NN, Arndt DC, McGrory BJ, Harris WH. The Harris hip score: comparison of patient self-report with surgeon assessment. *The Journal of arthroplasty.* 2001 Aug 31; 16(5):575-80. <https://doi.org/10.1054/arth.2001.23716>. PMID: 11503116.
- Kenzora JE, Mccarthy RE, J Drennan LO, Sledge CB. Hip fracture mortality: Relation to age, treatment, preoperative illness, time of surgery, and complications. *Clinical Orthopaedics and Related Research.* 1984 Jun 1; 186:45-56. <https://doi.org/10.1097/00003086-198406000-00008>.
- Gordon PC. The probability of death following a fracture of the hip. *Canadian Medical Association Journal.* 1971 Jul 10; 105(1):47.
- Kyle RF, Cabanela ME, Russell TA, Swiontkowski MF, Winquist RA, Zuckerman JD, Schmidt AH, Koval KJ. Fractures of the Proximal Part of the Femur. *Instr. Course Lect.* 1995; 44:227-53.
- Haidukewych GJ, Israel TA, Berry DJ. Reverse obliquity fractures of the intertrochanteric region of the femur. *J Bone Joint Surg. Am.* 2001;83:643-50 <https://doi.org/10.2106/00004623-200105000-00001>. PMID: 11379732.
- Wolfgang GL, Bryant MH, O'neill JP. Treatment of intertrochanteric fracture of the femur using sliding screw plate fixation. *Clin. Orthop.* 1982; 163:148-58. <https://doi.org/10.1097/00003086-198203000-00022>.
- Liang YT, Tang PF, Gao YZ, Tao S, Zhang Q, Liang XD, Han G, Cui G, Yang MY. Clinical research of hemiprosthesis arthroplasty for the treatment of unstable intertrochanteric fractures in elderly patients. *Zhonghua Yi Xue Za Zhi.* 2005; 85(46):3260-62.
- Davis TR, Sher JL, Horsman A, Simpson M, Porter BB, Checketts RG. Intertrochanteric femoral fractures - Mechanical Failure After Internal Fixation. *Bone and Joint Journal.* 1990 Jan 1; 72(1):26-31. <https://doi.org/10.1302/0301-620X.72B1.2298790>.
- Nordin S, Zulkifli O, Faisham WI. Mechanical failure of Dynamic Hip Screw (DHS) fixation in intertrochanteric fracture of the femur. *Medical Journal of Malaysia.* 2002; 56:12-17.

17. Kaufer H, Matthews LS, Sonstegard D. Stable fixation of intertrochanteric fractures: A Biomechanical Evaluation. *JBJS*. 1974 Jul 1; 56(5):899-907. <https://doi.org/10.2106/00004623-197456050-00002>.
18. Levy RN, Siegel M, Sedlin ED, Siffert RS. Complications of ender pin fixation in basicervical, intertrochanteric, and subtrochanteric fractures of the hip. *J. Bone Joint Surg*. 1983; 65(-A):66-69. <https://doi.org/10.2106/00004623-198365010-00009>.
19. Liu M, Yang Z, Pei F, Huang F, Chen S, Xiang Z. A meta-analysis of the Gamma nail and dynamic hip screw in treating peritrochanteric fractures. *International Orthopaedics*. 2010 Mar 1; 34(3):323-28. <https://doi.org/10.1007/s00264-009-0783-4>. PMID: 19401825, PMCID: PMC2899291.
20. Saarenpää I, Heikkinen T, Ristiniemi J, Hyvönen P, Leppilahti J, Jalovaara P. Functional comparison of the dynamic hip screw and the Gamma locking nail in trochanteric hip fractures: A matched-pair study of 268 patients. *International Orthopaedics*. 2009 Feb 1; 33(1):255-60. <https://doi.org/10.1007/s00264-007-0458-y>. PMID: 17943284, PMCID: PMC2899252.
21. Simpson AH, Varty K, Dodd CA. Sliding hip screws: Modes of failure. *Injury*. 1989 Jul 1; 20(4):227-31. [https://doi.org/10.1016/0020-1383\(89\)90120-4](https://doi.org/10.1016/0020-1383(89)90120-4).
22. Geller JA, Saifi C, Morrison TA, Macaulay W. Tip-apex distance of intramedullary devices as a predictor of cut-out failure in the treatment of peritrochanteric elderly hip fractures. *International Orthopaedics*. 2010 Jun 1; 34(5):719-22. <https://doi.org/10.1007/s00264-009-0837-7>. PMID: 19618186, PMCID: PMC2903170.
23. Wu CC, Shih CH, Lee MY, Tai CL. Biomechanical analysis of location of lag screw of a dynamic hip screw in treatment of unstable intertrochanteric fracture. *Journal of Trauma and Acute Care Surgery*. 1996 Oct 1; 41(4):699-702. <https://doi.org/10.1097/00005373-199610000-00017>. PMID: 8858031.
24. Wolfgang GL, Bryant MH, O'neill JP. Treatment of intertrochanteric fracture of the femur using sliding screw plate fixation. *Clinical Orthopaedics and Related Research*. 1982 Mar 1; 163:148-58. <https://doi.org/10.1097/00003086-198203000-00022>.
25. Johnson LL, Lottes JO, Arnot JP. The utilization of the Holt nail for proximal femoral fractures: A study of one hundred and forty-six patients. *The Journal of Bone & Joint Surgery*. 1968 Jan 1; 50(1):67-78. <https://doi.org/10.2106/00004623-196850010-00004>. PMID: 5638119.
26. Broos PL, Rommens PM, Geens VR, Stappaerts KH. Peritrochanteric fractures in the elderly - Is the Belgian VDP prosthesis the best treatment for unstable fractures with severe comminution? *Acta Chirurgica Belgica*. 1991; 91(5):242-49. <https://doi.org/10.1097/00005131-199112000-00010>. PMID: 1762006.
27. Claes H, Broos P, Stappaerts K. Peritrochanteric fractures in elderly patients: treatment with Ender's nails, blade-plate or endoprosthesis? *Injury*. 1985 Jan 1; 16(4):261-64. [https://doi.org/10.1016/S0020-1383\(85\)80016-4](https://doi.org/10.1016/S0020-1383(85)80016-4).
28. Sinno K, Sakr M, Girard J, Khatib. The effectiveness of primary bipolararthroplasty in treatment of unstable intertrochanteric fractures in elderly patients. *North Am. J. Med. Sci*. 2010; 2:561-68. <https://doi.org/10.4297/najms.2010.2561>. PMID: 22558568, PMCID: PMC3338223.

**How to cite this article:** Pangavane S., Challawar N., Kulkarni A., Nebhani N., Agrawal N. and Bhalerao B. Unstable Intertrochanteric Femur Fracture in Elderly Treated with Bipolar Hemiarthroplasty Versus Dynamic Hip Screw - A Prospective Comparative Study. *MVP J. Med. Sci*. 2019; 6(2):231-236.