

Cross Sectional Study of Fine Needle Aspiration Cytology in Neck Masses

Achala Ghanashyam Kamath¹ and Kirankumar Surendra Burse^{2*}

¹PG Resident, Department of Otorhinolaryngology, Dr. Vasantrao Pawar Medical College Hospital and Research Centre, Nashik - 422003, Maharashtra, India; kamath.achala@gmail.com

²Professor & Head, Department of Otorhinolaryngology, Dr. Vasantrao Pawar Medical College Hospital and Research Centre, Nashik - 422003, Maharashtra, India; drksburse@gmail.com

Abstract

Background and Objectives: This study is done to evaluate the role of FNAC in diagnosis of neck masses. A correlation was done between cytology and histopathology. To assess the usefulness of Fine Needle Aspiration Cytology in the diagnosis of neck masses. **Materials and Methods:** Data for this study was collected from patients attending OPD and admitted in tertiary hospital and research centre at the Department of Otorhinolaryngology and Department of Surgery. 50 patients presenting with neck masses to our institution between November 2014 to May 2016 were included in the study. A time bound cross sectional study design. After a detailed clinical examination, relevant investigations and a valid informed consent, Fine Needle Aspiration Cytology of the neck swelling was performed. Followed by biopsy and histopathological examination of the neck swelling. The result of Fine Needle Aspiration Cytology was correlated with result of Histopathological examination of neck swelling. Results: Benign lesions constituted the predominant cause of neck swellings in our study. The sensitivity, specificity and efficiency of Fine Needle Aspiration Cytology in our study was 55.6%, 100% and 92% respectively. Conclusion: Fine Needle Aspiration Cytology is an excellent first line method for investigating patients presenting with neck masses. Since the masses of the neck are easily accessible, Fine Needle Aspiration Cytology is a diagnostic procedure, which suits well for such a situation.

Keywords: Fine Needle Aspiration Cytology, Neck Mass

1. Introduction

A patient presenting with a mass in the neck is a common occurrence in clinical practice. The presence of a mass in the neck can be a cause of concern to both patients and the surgeon for the diagnosis.

Neck masses may be due to congenital, inflammatory, benign and malignant neoplastic conditions¹⁻³. Diseases of lymph nodes, thyroid, parotidglands, submandilar glands etc., may be responsible for neck masses. The presence of a neck mass poses a diagnostic dilemma for the surgeon and it is important to make an early and a proper diagnosis for further management of patients presenting with neck masses. Traditionally surgical biopsy and its histopathological study has remained the mainstay for the diagnosis and management of neck masses. Here the whole tissue is available for examination under microscope⁴.

The FNAC involves study of cells obtained by fine needle under vacuum⁵. Unlikebiopsy, the whole tissue

is not available for microscopic examination. It is still possible to have a high diagnostic accuracy. The biopsy has certain disadvantages like anaesthesia is needed for obtaining biopsy, reporting takes time and biopsy produces a scar over the operated area. The cost for a biopsy procedure is more whereas fine needle aspiration cytology is OPD/office procedure which does not require anaesthesia, diagnosis is obtained quickly, complications are almost nil and diagnostic accuracy is high. Therefore Fine Needle Aspiration Cytology helps in arriving at a rapid diagnosis of neck masses and hence in further management of neck masses.

2. Aims and Objectives

- To assess the usefulness of Fine Needle Aspiration Cytology in diagnosis of neck masses.
- To correlate the diagnosis by Fine Needle Aspiration Cytology and Histopathological examination for patients who will undergo excision.

3. Methods and Materials

- Study setting: Data for this study was collected from patients attending OPD and admitted in, Department of Otorhinolaryngology and Department of Pulmonology and Department of Surgery of a medical college and a tertiary health care centre.
- Type of study: Time bound cross sectional study design.
- Study duration: 1 1/2years (1st November 2014 to 31st may2016).
- Sample size: Patients of neck swelling presenting in our hospital from 1st November 2014 to 31st may 2016.

3.1 Eligibility Criteria

- **Inclusion Criteria:** Patients presenting with neck swelling.
- **Exclusion Criteria:** Patients not willing to undergo fine needle aspiration cytology and histopathological examination.

4. Results

Most of the patients presented within 12 months of the onset of symptoms. 44% (22 patients) presented within 6 months. Only 6% (3patients) presented within 1 month of onset of symptoms. 26% (13 patients) presented between 7-12 months. 24% (12 patients) presented with symptoms >12 months. A case of non-specific sialadenitis presented after 8 days, was the earliest presentation. A patient with pleomorphic adenoma presented after 4 years of onset of symptoms. This was the patient who presented very late.

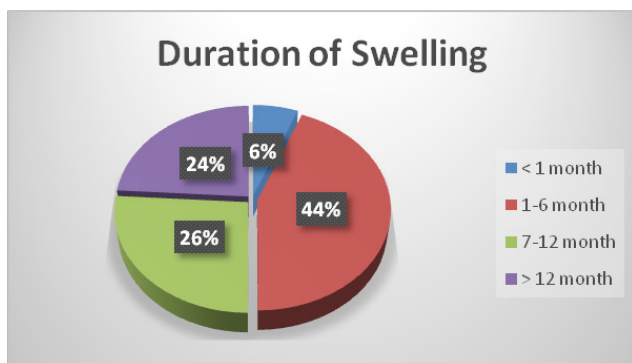


Figure 1. Duration of swelling.

4.1 Laterality Distribution

Majority of the patients had a unilateral neck mass⁵. 62% (31 patients) had a unilateral neck mass. 30% (15 patients)

had a right sided neck mass and 32% (16 patients) had a left sided neck mass.

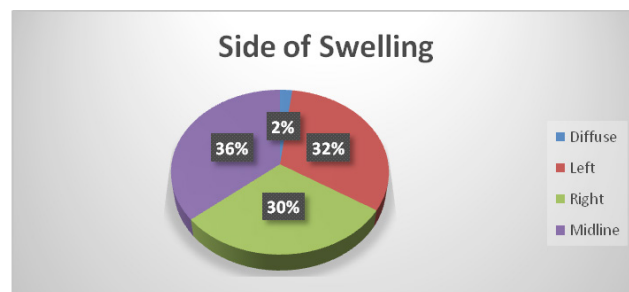


Figure 2. Side of swelling.

4.2 Causes of Neck Masses

The maximum number of neck masses was due to thyroid enlargement consisting 48% of the cases^{6,7}. Lymph node constituted 28% of the cases.

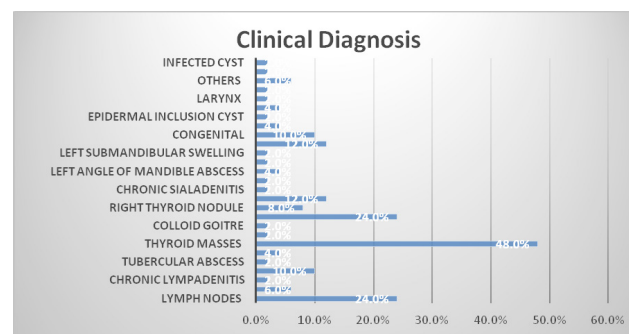


Figure 3. Causes of neck mases

4.3 Sensitivity and Specificity of FNAC in our Study

The sensitivity, specificity and accuracy of fine needle aspiration cytology in detecting malignant lesions in our study are 55.6%, 100% and 92% respectively. Positive predictive value and Negative predictive value of FNAC in detecting malignancy is 100% and 91.1% respectively.

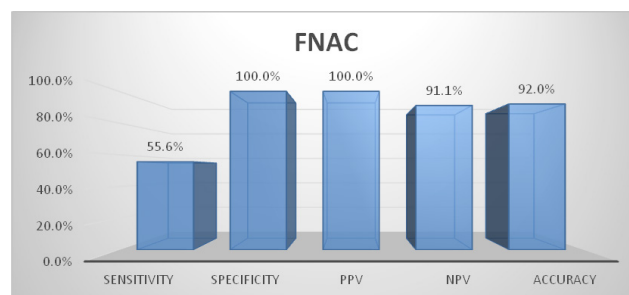


Figure 4. Sensitivity and specificity of fnac inour study

5. Conclusion

From this study it can be concluded that fine needle aspiration cytology is a relatively atraumatic, well tolerated, safe procedure which can be readily performed in outpatient set up. This technique is an excellent first line method for investigating the patients presenting with neck masses. Since the masses of the neck are easily accessible, FNAC is a diagnostic procedure, which suits well for such a situation. Apart from the high accuracy rate of FNAC, this technique is rapid, safe and painless. It can be especially valued because it is an out-patient procedure; done without prior preparation or anaesthesia. Both, FNAC procedure and interpretation are quick and is a cost-contained procedure. It is eminently suitable for all age groups. The cooperation from the patients for the procedure, including children is excellent. In the neck, it obviates the need for an excision biopsy in non-malignant conditions, thereby reducing the chances of an ugly scar in the exposed area. The chances of complications, such as infection, haemorrhage are almost nil. However, it must never be thought as a replacement for histopathological diagnosis in all cases. The two have to complement each other, along with the other newer diagnostic techniques for a diagnosis to be infallible and accurate for further management⁸⁻¹⁰.

6. References

1. Gluson M, Browing GG, Burton MJ, Clarke R, Hibbat J,

- Jones NS, et al, editors. Surgical anatomy of the neck. Scott-Brown's Otorhinolaryngology, head and neck surgery. 7th ed. Great Britain: Edward Arnold (Publishers) Ltd; 2008. p. 1739-53.
2. Watkinson JC, Gaze MN, Wilson JA, editors. Metastatic neck disease. Stell, Maran's Head and Neck Surgery. 4th ed. Hodder Arnold; 2000. p. 197-214.
 3. Standring S. Neck. Berkovitz BKB, editor. Gray's Anatomy. 39th ed. Elsevier Churchill Livingstone Publications; 2005. p. 531-66.
 4. Drake AF, Hulka GF. Congenital neck masses. The neck diagnosis and surgery. Mosby Year Book Inc; 1994. p. 93-107.
 5. Das S. Swellings in the neck. A textbook on Surgical Short Cases. 3rd ed. Calcutta, India; 2007. p. 98-120.
 6. Griffin GE, Sisson JGP, Chiodini PL, Mitchell DM. Diseases due to infection. Davidson's principles and practice of medicine. 18th ed. Churchill Livingstone Publications; 1999. p. 57-190.
 7. Langdon JD. Salivary gland disorders. Bailey and Love's short practice of surgery. 23rd ed. Arnold Publications; 2000. p. 651-88.
 8. Krakowski ZH. The thyroid gland and the thyroglossal tract. Bailey and Love's short practice of surgery. 23rd ed. Arnold Publication; 2000. p. 707-33.
 9. Mc Gurit WF. Neck masses: Differential diagnosis and therapeutic approach. The Neck Diagnosis and Surgery. Mosby Year Book Inc; 1994. p. 73-89.
 10. Mackie MJ, Ludlam CA, Haynes AP. Diseases of the blood. Davidson's Principles and Practice of Medicine. 18th ed. Churchill Livingstone Publications; 1999. p. 737-800.