



An Ayurvedic Intervention for Subconjunctival Hemorrhage (SCH) Resulting in Early Alleviation of Disease — A Case Report

Madhav Madhukar*, Pallavi Jagtap and Mayur Shiralkar

Department of Shalakya Tantra, Dr. D.Y. Patil College of Ayurved and Research Centre, Dr. D.Y. Patil Vidyapeeth (Deemed to be University), Pimpri, Pune – 411018, Maharashtra, India; bipul840@gmail.com

Abstract

Introduction: Subconjunctival Hemorrhage (SCH) is a common condition of the eye that has distinct characteristic features, such as the acute appearance of a sharply circumscribed redness of bleeding underneath the conjunctiva in the absence of discharge, and inflammation in the affected areas, which is painless. We are now disclosing a case of subconjunctival bleeding caused by local minor trauma and eye rubbing. This case was unique as the healing time, which was usually 1 to 2 weeks, was reduced to 5 days after the intervention of ayurvedic formulations. **Case Presentation:** A 60-year-old man who had redness in his left eye for one day came to the OPD setting. Redness and inflammation were present, as shown by direct clinical questioning. Later, a clinical examination confirmed both symptoms. A subconjunctival hemorrhage was confirmed by the way the eye appeared. **Conclusion:** Subconjunctival hemorrhage may exhibit signs of other conditions that pose a risk to the eyes. To make a distinction between those causes and localized subconjunctival hemorrhage, a clinical assessment was necessary.

Keywords: Aschyotana, *Netramritam* Eye Drop, Photophobia, Subconjunctival Haemorrhage

1. Introduction

A benign condition known as subconjunctival hemorrhage frequently results in acute ocular redness¹. Generally, Sites for SCH are usually inferior and temporal regions of the globe. If it is to be said, the precise temporal region is the one which is mostly affected². Localization of trauma is usually seen in comparison with SCH arising from a disorder that is of vascular origin (Figures 1 and 2)². Summer time is when SCHs are more prevalent. This is the main reason for the increase in the frequency of traumatic causes of SCH in this season³.

Subconjunctival hemorrhages do not seem to have any sort of gender discrepancy. However, in young males, the prevalence rate of SCH is found to be high. It is usually seen in a person performing heavy and rigorous active tasks⁴. The elastic and connective

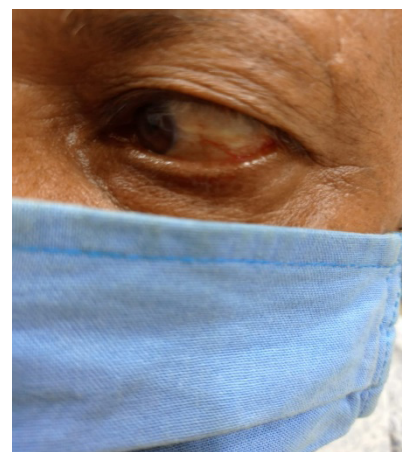

Figure 1. Subconjunctival hemorrhage after treatment.

tissues that make up the fibrous connections under the conjunctiva weaken with age, which may account for older patients' easier bleeding to spread⁵.

*Author for correspondence

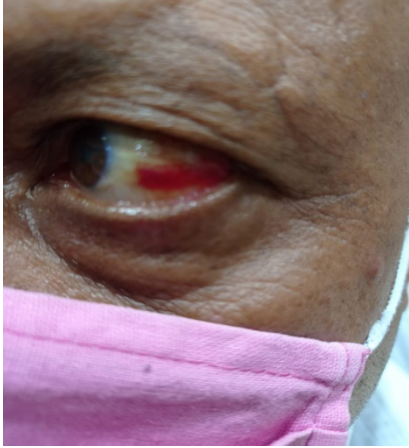


Figure 2. Subconjunctival hemorrhage before treatment.

2. Patient Information

The patient who was exhibiting the symptoms of subconjunctival hemorrhages in the left eye was a 60-year-old male, resident of Pune, Maharashtra. The main symptoms of the patient were redness in the left eye for one day and mild pain in the left eye for one day. K/C/O- Diabetes Mellitus Type 2
No H/O – Food allergy, drug allergy, depression

3. Clinical Findings

Temperature - Afebrile
Pulse - 80 beats/min
Blood Pressure - 138/86 mm of Hg
Respiration Rate - 18 / min
HbA1C - 6.3%

4. Case Report

A 60-year-old man with a history of type 2 diabetes who takes Glimiprex MF 1/500 1 Tab daily is in regular control, with a routine prior ophthalmological history, who visited the *Shalakya tantra* OPD referring a one-day episode of redness in the left eye. It started after vigorously rubbing the left eye. After direct clinical questioning, he referred to photophobia, and left eye pain, all of which had started the day before. He denied secretions, foreign body sensations, reduced visual acuity, or any other symptoms. A localized hemorrhage on the left lateral and inferior conjunctiva of the left

eye (Figure 1) was discovered, with no corneal lesions or abrasions. The patient's best corrected visual acuity was 6/9p in the right eye and 6/6p in the left eye. No foreign objects were visible upon eyelid eversion. The photomotor reflexes, accommodation reflexes, and ocular motility of both pupils were round, regular, and reactive.

After resolution, SCH provides a good visual prognosis. In most cases, vision is not hampered. Without observable risk factors, the recurrence rate for spontaneous SCH is around 10%, and it rises if patients are receiving anticoagulant or antiplatelet therapy⁵.

5. Therapeutic Intervention

He was given ayurvedic pharmacological intervention for 5 days straight - *Yashtimadhu ghritha aschyotana* – 8 drops in the left eye and *Netramritam* eye drop – 1 drop in the left eye thrice a day. When the patient continued to show no symptoms, he was discharged and given a note for the following day. He became completely symptomless five days after the hemorrhages started to become less noticeable. The full extent of the hemorrhage, hemorrhagic spots, and symptoms had disappeared by the end of the first week.

5.1 Bahya Chikitsa (External Medication)

- *Yashtimadhu Ghritha Aschyotana* (Ghee prepared with *Glycyrrhiza glabra* Linn.): 8 drops TDS for 5 days.
- *Netramritam*

For five days, use one drop TDS.

Netramritam contains the following ingredients:

Lodhratwak (Symplocos racemosa) - This herb is primarily used to treat bleeding and eye disorders. It has been mentioned in *Ayurveda* since the time of *Sushruta*.

Sevyam

Sasi

Himambu

Hima (Cinnamomum camphora) - Camphor Padmak (*Prunus cerasoides*).

5.2 Abhyantar Chikitsa (Internal Medicine)

Vasa, guduchi, nimba, triphala, and patola. Each of the aforementioned five medications, which were produced

by Sudha Tatva Pharmacy of the Dr. D.Y. Patil College of Ayurved and Research Center in Pimpri, Pune, were taken in powder form, 500 mg BD each, with honey, for five days. Our patient got the maximum benefits in the least time duration from *ayurvedic* intervention.

6. Methods of Instillation of Eye Drops

Taking all the aseptic measures required, *aschyotana* and eye drops were instilled in the affected eye.

6.1 Methodology

- Bright red patch on the temporal side of the sclera of the left eye was observed on the first day of the onset of symptoms of Subconjunctival Hemorrhage.
- A hemorrhage assessment was done every day for five days until the healing was complete.
- Photophobia was reduced after the instillation of *yestimadhu aschyotana* and *netramritam* eye drops in the left eye.
- A close look was given to observe the healing pace of subconjunctival hemorrhage after giving *ayurvedic* intervention.

7. Results

Hypertension was the most prevalent ailment in spontaneous SCH. All patients were found to have SCH that predominated in the temporal regions. In spontaneous SCH, nasal and temporal areas were equally affected, whereas temporal areas were more affected in traumatic SCH. Men were more likely than women to experience traumatic etiology.

So, *Yashtimadhu ghruta* is a potent pitta shaman, and *Vrana Hara* is beneficially instilled in the patient's left eye along with *Netramritam* eye drops, which are prepared by Arya Vaidya Sala, Kottakkal.

- A minimum hospital stay is required.
- Reduced healing time.
- It is inexpensive.

8. Discussion

An increase in the number of people wearing contact lenses and having various ocular surgeries has further contributed to the traumatic incidence of SCH. Defects

in the surface material of hard contact lenses had contributed to traumatic incidence of SCH^{6,7}. Even local anesthesia given during ocular surgeries such as sub-tenon's block raises the chance of SCH⁷.

Very often, it is seen that local trauma and foreign bodies are the cause of SCH. The particular patient is unable to recall anything as a result. SCH can arise following orbital fractures. When there is no globe trauma, the SCH, which appears to be coming from the fornix, is used to identify basilar skull fractures⁸.

Diabetes and hyperlipidemia along with vascular diseases is the biggest risk factor for spontaneous SCH. Blood vessels become fragile and rupture due to the effect of these diseases. SCH is seen in patients with hypertension even whether the patient is on medication or not. At the initial presentation of hypertension spontaneous SCH is the predictor^{9,10}.

Anticoagulants like warfarin or heparin are prescribed to patients with vascular disorders. Aspirin and P2Y12 inhibitors like clopidogrel can both increase the risk of developing SCH. The risk of SCH exists even if INR is in the therapeutic range¹¹. The SCH occurs between the conjunctiva and the episcleral. Substantia proper is the home of blood elements. As the hemoglobin and other blood components degrade, the eye also changes hue, turning blue and yellow. Over the course of 1-2 weeks, the blood is removed¹².

9. Probable Mode of Action

Yashtimadhu Ghruta Aschyotana pacifies the aggravated *pitta* and acts on ulcerative changes in layers of sclera as it has the property of *tridoshghna*, *shothhar*, *shoolhar* and most importantly *vranropan*¹³.

Netramritam Eye Drop helps in reducing the blood element accumulation in substantia propria through its *rakta stambhak* properties¹⁴.

Vasa acts as a coolant by arresting bleeding and alleviating burning sensation¹⁵.

Guduchi is a potent medicine that acts as an antioxidant and is capable of wound healing¹⁶.

Nimba acts by decreasing the secretion of extra blood elements and is considered pitta shaman¹⁷.

Patola pacifies *tridosha* and helps in decreasing the overall healing time of SCH¹⁸.

Triphala being *tridosha shamak* and one of the best antioxidants acts directly on active regeneration¹⁹.

10. Acknowledgments

The authors are grateful to respected Professors for continuously motivating us to complete this research work. We are grateful for the help done by Dr. Santosh Rahinj, Dr. Anand Kale and Dr. Shubhangi Kale. We would like to appreciate the untiring support of Dr. Atri Ghosh, and Dr. Kiran for their relevant ideas, which helped us during the completion of this case report.

11. References

1. Tarian B, Kiratli H. Subconjunctival hemorrhage: Risk factors and potential. *Clinical Ophthalmology*. 2013; 7:1163-1170.
2. Mimura T, Yamagami S, Usui T, Funatsu H, Noma H, Honda N, *et al*. Location and extent of subconjunctival hemorrhage. *Ophthalmologica*. 2010; 224(2):90-95. <https://doi.org/10.1159/000235798>
3. Fukuyama J, Hayasaka S, Yamada K, Setogawa T. Causes of subconjunctival hemorrhage. *Ophthalmologica*. 1990; 200(2):63-7. <https://doi.org/10.1159/000310079>
4. Mimura T, Usui T, Yamagami S, Funatsu H, Noma H, Honda N, *et al*. Recent causes of subconjunctival hemorrhage. *Ophthalmologica*. 2010; 224(3):133-137. <https://doi.org/10.1159/000236038>
5. Cugini C, Iannone A, Bartolini A, Fiore T, Fierro T, Gresele P. Reasons for visits to an emergency center and hemostatic alterations in patients with recurrent spontaneous subconjunctival hemorrhage. *European Journal of Ophthalmology*. 2016; 26(2):188-192. <https://doi.org/10.5301/ejo.5000692>
6. Mimura T, Yamagami S, Mori M, Funatsu H, Usui T, Noma H, Amano S. Contact lens-induced subconjunctival hemorrhage. *American Journal of Ophthalmology*. 2010; 150(5):656-665. <https://doi.org/10.1016/j.ajo.2010.05.028>
7. Liu W, Li H, Qiao J, Tian T, An L, Xing X, *et al*. The tear film characteristics of spontaneous subconjunctival hemorrhage patients were detected by Schirmer Test I and tear interferometry. *Molecular Vision*. 2012; 18:1952-1954.
8. King AB, Walsh FB. Trauma to the head with particular reference to the ocular signs; injuries involving the hemispheres and brain stem; miscellaneous conditions; diagnostic principles; treatment. *American Journal of Ophthalmology*. 1949; 32(3):379-398. [https://doi.org/10.1016/0002-9394\(49\)91931-5](https://doi.org/10.1016/0002-9394(49)91931-5)
9. Kittisupamongkol W. Blood pressure in subconjunctival hemorrhage. *Ophthalmologica*. 2010; 224(5):332. <https://doi.org/10.1159/000313835>
10. Pitts JF, Jardine AG, Murray SB, Barker NH. Spontaneous subconjunctival hemorrhage—A sign of hypertension? *British Journal of Ophthalmology*. 1992; 76(5):297-299. <https://doi.org/10.1136/bjo.76.5.297>
11. Bodack MI. A warfarin-induced subconjunctival hemorrhage. *Optometry*. 2007; 78(3):113-8. <https://doi.org/10.1016/j.optm.2006.10.015>
12. Doshi R, Noohani T. Subconjunctival Hemorrhage. [Updated 2023 Feb 20]. In: StatPearls [Internet]. Treasure Island (FL): StatPearls Publishing; 2023.
13. Available from: <http://www.energy.sk/info/menux2055x.asp>
14. Available from: www.amrit-veda.com
15. Kumar S, Dwivedi KN. A brief review on medicinal property of vasa (*Adhatoda vasica* Linn Nees) from kosha and nighantus. 2019. Available from: https://www.researchgate.net/publication/332012649_A_BRIEF_REVIEW_ON_MEDICINAL_PROPERTY_OF_VASA_ADHATODA_VASICA_LINN_NEES_FROM_KOSHA_AND_NIGHANTUS
16. Rawat N, Roushan R. Guduchi; A potential drug in Ayurveda. https://www.researchgate.net/publication/331087814_GUDUCHI_A_POTENTIAL_DRUG_IN_AYURVEDA
17. API (Ayurvedic Pharmacopeia of India) vol-1 page-161, vol-1 page-53, vol-2 page-132, vol-3 page-149.
18. Vikas G, Pagoch SS. Phytopharmacological review of *Trichosanthes dioica* (Patola). *International Ayurvedic Medical Journal*. 2014; 2(3):322-337.
19. Peterson CT, Denniston K, Chopra D. Therapeutic uses of *Triphala* in Ayurvedic medicine. *Journal of Alternative and Complementary*. 2017; 23(8):607-614.